

NHS Borders

Surgical Department

Consultant Surgeons:

Mr M Berlansky (Head of Clinical Service)

Mr K Pal

Mr J Young

Mr S Al-Sabounchi

Miss D Twelves

Mr S Vallabhajousula

Borders General Hospital

Melrose

Roxburghshire

TD6 9BS

Telephone: 01896 826000

www.nhsborders.org.uk

Dictated: 17/8/2023

Date: 25/8/2023

Our Ref: DJT/jt/068277W

CHI: 2202669701

Enquiries to: Caroline Lawrenson

Direct Line: 01896 826919

E-mail: Caroline.Lawrenson@borders.scot.nhs.uk



Dr Mollart

Selkirk Medical Practice

The Health Centre

Viewfield Lane

Selkirk

TD7 4LJ

Dear Dr Mollart

RE: MISS KATRINA ROBERTSON DOB: 22-02-1966

21 ANDERSON ROAD SELKIRK TD7 4EB

Thanks for referring this 57 year old lady who noticed a lump beyond the upper edge of her left breast. It is in the 1 o'clock position and consistent with a benign lipoma on examination and on ultrasound scan. Her last mammogram was normal with screening last year and she has been reassured and discharged.

Yours sincerely

A handwritten signature in black ink, appearing to be 'D Twelves', written in a cursive style.

Miss D Twelves

Consultant Breast & General Surgeon

Breast Clinic

Borders General Hospital



F 22/02/1966
2202669701

ROBERTSON
21 ANDERSON ROAD

KATRINA

MRN: 068277W

SELKIRK SELKIRKSHIRE
TD7 4EB AA CRAGG 16085/1

Telephone Number:-

17/8/23

Clinic date :-

Date of referral:-

Date referral received :-

Referred by :-

GP Screening Others please specify

57

Presentation Details

Duration of symptoms (Weeks)



7 wks

Symptoms

- Lump
- Pain
- Discharge
- Change
- Other

Side

- Left
- Right
- Bilateral
- Not recorded

Menopausal Status

- Pre
- Peri
- Post
- Hx
- Not recorded
- Inapplicable

Significant family history:-

LMP:- / / 20

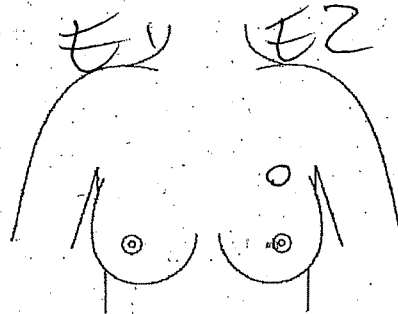
Past history of breast disease :-

Family History :-

Past Medical history:-

Drug History :-

Clinical findings



Side	Size cm)	Vol (ml)	O'clock

Investigation

Mammography

- None
- To be arranged
- Normal
- Benign
- Suspicious probably benign
- Highly suspicious
- Carcinoma (Radiologist confirmation awaited)

- FNA
- Trucut
- Biopsy
- Cyst aspiration
- USS Arranged

Clinical Diagnosis

- Normal
- Benign
- Probably benign
- Suspicious
- Malignant

Plan

- Discharge
- O.P review Months
- Medical Rx
- Surgical Rx
- Minor Op-
- D.P.U
- In Patient
- Await Results.

Drug Prescription / Comments

--

Referral appropriate

Yes No

GP referral urgent

Yes No

Urgent appropriate

Yes No

Chaperoned by :-

Diagnostic Imaging Report

CHI No. : 2202669701 Patient Name : Robertson, Katrina Patient Address : 21 ANDERSON ROAD Selkirk SELKIRKS TD7 4EB DOB : 22/02/1966 Gender : Female	Lead Consultant : Dominique Twelves Specialty : General Surgery Address : Borders General Hospital Melrose TD6 9BS Ward/Clinic : Outpatients H Attendance No. : 40409743
--	--

Examination(s) : US Breast Lt	Exam Date : 17 August 2023
Accession(s) : B1234040974301	Report Date : 17 August 2023

Authorised

Clinical Indications:

Weeks left ~1.5cm lump 1:00 beyond superior border of breast (E2 lipoma?); NHSBP MMG last year normal; patient happy to be discharged by radiology if imaging benign

US Breast Lt

The third of concern within the peripheral left upper breast was examined. Several hyper reflective well defined areas correlate with the palpable lesion. The provoking lesion measures 30 x 13 x 26 mm representing a benign lipoma. Several further smaller lipomas up to around 26 mm lying immediately adjacent. The left upper breast was examined and is otherwise normal, no suspicious features.

Opinion:

Left breast, benign, U-2

Dr Ben Ward. GMC 6050339.
Consultant Radiologist
NHS Borders

Received	<input type="checkbox"/>
Notes Required	<input type="checkbox"/>
Test Arranged	<input type="checkbox"/>
21 AUG 2023	
Letter	<input type="checkbox"/>
No Action	<input checked="" type="checkbox"/>
OPD Appt.	<input type="checkbox"/>

Reported by	Dr Ben Ward. GMC 6050339. Consultant Radiologist NHS Borders
Authorised by	Dr Ben Ward. GMC 6050339. Consultant Radiologist NHS Borders

