

NHS Confidential: Personal data about a patient

From: oohfailedemail@lanarkshire.scot.nhs.uk
 Sent: 12 June 2007 01:00
 To: OOH62031@LANARKSHIRE.SCOT.NHS.UK
 Subject: Call #18378 11-Jun-2007

Call #: 18378 Received NHS24: 11-Jun-2007 22:58
 Full cover

Patient's Name: James Haney CHI Number: 0209615214
 Date of birth: 02-Sep-1961 (Age: 45 years) Received PCES: 23:19
 Sex: Male Passed : :
 Home Address: Centenary Crescent Bellshill Advised : :
 Main Door ML4 1B2 ()
 Current Address: {}
 Tel No: 01698 744119 Origin: NHS24 Arrived : :
 Urgency: NHS24 Advised Type: NHS24 Advice Departed : :
 Consulted by: Own Doctor: Park, D

Message received:
 SHARP CHEST PAINS/HOT & CLAMMY 1DAY SEE AV

NHS24 Consultation Begin: 11-Jun-2007 23:04
 NHS24 Consultation End: 11-Jun-2007 23:13
 NHS24 Consultation by: Triage Nurse

NHS24 Clinical Summary:
 Clinical summary created: 11-Jun-2007
 SHARP. JAGGY PAINS IN CHEST, HOT AND CLAMMY. NOT NEW SYMPTOMS. PRESCRIBED
 MELONICAMB TODAY. BUT NOT FILLED PRESCRIPTION YET. ADVISED COCODAMOL AND TO
 CALL BACK IF NO BETTER. ON CITALOPRAM FOR DEPRESSION. HAD TREADMILL AND
 CARDIAC CHECKS NEG. RECENTLY.

NHS24 Outcome: PE advised to contact practice within 36 Hrs - Coop to forward to
 Practice

Advised: 23:04 Advised by: Triage Nurse

Time of Visit/Base: 23:04 Consulting Doctor:

Past Medical History:

Examination:

Outcome:

Final Treatment:


Prescriptions:

UCS Outcome:

Followups:

Call #: 18378 Patient's Name: James Haney

NHS Confidential: Personal data about a patient



NHS Confidential: Personal data about a patient

From: oohfailedemail@lanarkshire.scot.nhs.uk
 Sent: 06 May 2007 01:00
 To: OOH62031@LANARKSHIRE.SCOT.NHS.UK
 Subject: Call #92784 05-May-2007

Call #: 92784 Received NHS24: 05-May-2007 17:49
 Full cover

Patient's Name: James Haney CHI Number: 0209615214
 Date of birth: 02-Sep-1961 (Age: 45 years)
 Sex: Male Received PCES: 18:59
 Home Address: 7 Centenary Crescent Bellshill Passed : 18:59
 Main Door ML4 1BZ () Advised :
 Current Address:
 ()
 Tel No: 01698 744119 Origin: NHS24 Arrived : 21:12
 Urgency: Within 4 Hours Type: PCC Departed : 21:19
 Consulted by: Own Doctor: Park, D

Message received:
 LACB SHAKING/WORSE THAN USUAL TODAY/SEE AV,

NHS24 Consultation Begin: 05-May-2007 18:45
 NHS24 Consultation End: 05-May-2007 18:51
 NHS24 Consultation by: Triage Nurse

NHS24 Clinical Summary:
 Clinical summary created: 05-May-2007
 DIZZY AND SHAKEY. ANXIOUS WITH CRAMPY CHEST PAIN. SAW OWN GP 2/7 AGO HAD
 CITALOPRAM INCREASED TO 20MG. SHAKEY EPISODES HAPPEN 2-3 TIMES A DAY MAKING PT
 MORE ANXIOUS. PT OTHERWISE WELL. PMH PT SUFFERS FROM ANXIETY. PCEC 4HRS HUB
 TO ARRANGE PLS.

NHS24 Outcome : Attend PCEC within 4 hrs
 Advised: 18:45 Advised by: Triage Nurse

Time of Visit/Base: 21:12 Consulting Doctor:

Past Medical History:
 started citalopram over 2 week ago 10mg increased the dosage to 20mg
 on wednesday complaining of feeling light headed sometime no dizziness

Examination:
 temp 36.5 chest clear BP 110/70 HS nad

Outcome:
 depression

Final Treatment:
 explained it is normal to increase the dosage after a week
 continue the medication

Prescriptions:

PCS Outcome:
 depression

Followups:
 follow up message (Return To Gp Only If Condition Not Resolved)

Call #: 92784 Patient's Name: James Haney

Scanned Document
13-May-2026 LIZMC
Additional: Scanned Document

Filename: igprda202605131431290.pdf
Extension: .tif
Pages:

NHS Confidential: Personal data about a patient

Clinical & Counselling Psychology Services
Motherwell/Clydesdale Department

Rute Building
Harrowoodhill Hospital
Harrowood
SHOTS ML7 4LA



Dr Gaddis
[redacted] Medical Centre
2 Pollock Street
Bellshill ML4 1QD

Dictated: 22/02/08
Typed: VB
Our Ref: VB

Enquiries to: V Braunton
Direct Line: 01501 824571/2 or 824510
01501 824515

Dear Dr Gaddis

Re: James Haney (2/9/61) 7 Centenary Crescent Bellshill ML4 1BZ

Further to my copy letter of 5/12/07, I write to update you on Mr Haney's contact with Psychology Services.

Following two assessment sessions, Mr Haney attended for three sessions of therapy during which we started to look at possibilities for behavioural change and cognitive re-framing in order to help with his low mood and high anxiety. Mr Haney also took the opportunity to explore his sense of grief regarding his sense that the family had, over the past several years, disintegrated. He appeared to engage reasonably well in session, and had made some changes particularly in how he spent his day which he felt had benefited his mood.

However, Mr Haney defaulted from his most recent appointment (5/2/08) and has not replied within the stipulated timeframe to a written enquiry regarding his wish to continue with further sessions. I assume, therefore, that further input is not required at present and I am discharging him from clinic.

Yours sincerely

Veronika Braunton
Cognitive Behavioural Therapist

cc E [redacted] Senior Charge Nurse, Psychiatric Assessment Team, Monklands Hospital,
Monkscourt Avenue, Airdrie ML6 0JS

TELL NORMAL	<input type="checkbox"/>
SCRIPT	<input type="checkbox"/>
SPEAK TO DR/NURSE	<input type="checkbox"/>
ATTEND	<input type="checkbox"/>
FILE	<input checked="" type="checkbox"/>



LAT100

Scanned Document
 13-May-2026 LIZMC
 Additional:Scanned Document

Filename: igprda202605131431270.pdf
 Extension:.tif
 Pages:

NHS Confidential: Personal data about a patient

Monklands Hospital
 Monkscourt Avenue
 Airdrie
 Lanarkshire ML6 0JS
 Switchboard: 01236 748748

NHS
 Lanarkshire

Department of General Surgery
 Consultant: Mr A [REDACTED]
 Direct Line to Secretary: 01236 742142
 Direct Fax: 01236 712547

AMD/EC/8138603

Ext: 2142

Clinic: 13th March 2009
 Typed: 8th April 2009

Dr CA [REDACTED]
 [REDACTED] Medical Centre
 2 Pollock Street
 Bellshill

Dear Dr [REDACTED]

JAMES HANEY DOB 02 09 61 CHI NO 0209615214
 9 COMMUNITY PLACE BELLSHILL

TELL NORMAL	<input type="checkbox"/>
SCRIPT	<input type="checkbox"/>
SPEAK TO DR/NURSE	<input type="checkbox"/>
ATTEND	<input type="checkbox"/>
FILE	<input type="checkbox"/>

Thank you for asking me to see this patient who has noticed a change in his bowel habit. This has been associated with quite marked tenesmus. He has also had occasional bleeding from his back passage. He is uncertain about any weight loss and certainly feels his appetite is diminished. He is also having occasional colicky abdominal pain. He is a non smoker and drinks alcohol only very occasionally. There is no family history of bowel disease. I see he is married with two children, both of whom [REDACTED] the family home. On examination his abdomen is soft non-tender and there is no palpable organomegaly. Rectal examination while difficult did not reveal any gross abnormalities. I think given his symptom profile it would be appropriate for him to have an urgent colonoscopy and I will arrange for this to be carried out.

Yours sincerely

A [REDACTED]

Mr A [REDACTED]
 Consultant Colorectal Surgeon

LAT100

NHS Confidential: Personal data about a patient

NHS Lanarkshire

COLONOSCOPY REPORT

Name: James HANEY, 02/09/1961 (M) Address: 9 Community Place
CHI No: 0209615214 Bellshill
Case note no.: 8138603 Lanarkshire
ML4 2DG

Procedure date
7th May 2009

GP: Dr CA [redacted]
2 Pollock Street
Mossend
Bellshill
Lanarkshire
ML4 1QD

Priority: Routine
Status: Outpatient/NHS
Hospital: Monklands Hospital

Referring Cons: Mr A [redacted]
(Monklands surgeons)

Consultant/Endoscopist

Mr A [redacted]
Nurses: SN L [redacted]
SN Rae [redacted]

Indications

Change in bowel habit.

Report

Bowel preparation with Fleet was good.
A digital rectal examination was performed.
The colonoscope was inserted via the anus to the caecum, insertion confirmed by terminal ileal biopsy. The caecum was identified positively by the ileocecal valve, the tri-radiate caecal fold and ileal intubation.
Mucosa: patchy mild atrophy at (b).
The examination to the limit of insertion was normal.

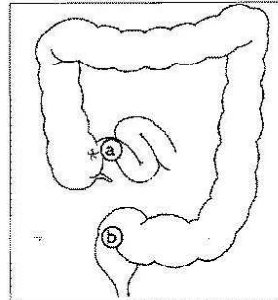
Instruments
MK - CF Q260DL 2310058
Disposable forceps

Premedication
Midazolam (IV) 4 mg
Pethidine (IV) 50 mg

Follow up

Awaiting pathology results. Return to the referring surgeon and review will be in the SOPD in 6 weeks.

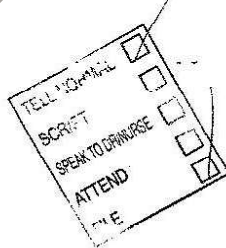
Mr A [redacted]
Consultant Surgeon



a: Terminal ileum
b: Distal sigmoid

Specimens taken

Biopsy (x1 site a and x4 site b)



THIRD PARTY COPY

Scanned Document
13-May-2026 LIZMC
Additional: Scanned Document

Filename: igprda202605131431240.pdf
Extension: .tif
Pages:

NHS Confidential. Personal data about a patient

MONKLANDS HOSPITAL
Monkscourt Avenue
Airdrie
Lanarkshire ML6 0JS



Department of General Surgery
Consultant: Mr [redacted]
Secretary ☎ 01236 712142
236 760015
E-mail ✉ norma.[redacted]@scot.nhs.uk

AM/AMD/8138603/CHI 0209615214

Mr [redacted] & [redacted] Colorectal Nurses Page 351
Isabell [redacted] & [redacted] Speirs Stoma Care Nurses Page 205

Mr [redacted] Colorectal Clinic 7th August 2009
Dictated 7.8.09
Typed 24.8.09

Dr [redacted]
[redacted] Medical Centre
2 Pollock Street
Mosend
BELLSHILL

Dear Dr Kelly

James Haney 9 Community Place Bellshill Date of birth 2.9.61

Your patient failed to attend my clinic today for follow up.

Just a note to let you know that the routine biopsies taken at the time of his colonoscopy did not show any worrying features.

I presume that his symptoms have now settled and have discharged him back to your care.

Yours sincerely

[Signature]
Mr [redacted] MD FRCS
Consultant Colorectal Surgeon

TELL NORMAL
SCRIPT
SPEAK TO OPERAISE
ATTEND
FILE

LAT109

www.nhs.gov.uk

SL070 v1 0208

NHS Confidential: Personal data about a patient

Wishaw General Hospital

32720



Outpatient Recommendation

(To be taken to your General Practitioner and if deemed necessary will supply a prescription)
 (Please hand in this letter at your G.P.'s Surgery and call back after two working days)

Outpatient Clinic: DERM
 Consultant: N.J. Wainwright
 Diagnosis: BCC + Psoriasis

8138603
 M 02/09/1981
 HANEY JAMES
 9 COMMUNITY PLACE
 BELLSHILL
 LANARKSHIRE ML4 2DG
 CHI. 0209615214

Mr / Mrs / Miss
 Weight (kg)
 Height (cm)

Medicine Allergies:

Drug on Lanarkshire Formulary	Yes / No
If No, reason for prescription	

Dear Dr. Findlay

This patient attended the DERM clinic on 23/2/10 and I would ask you to consider prescribing the following additional/alternative (delete) treatment within 48 hours instead of

TO BE PRINTED IN BLOCK CAPITALS IN POINT PEN

Recommended Medicine	Dose	Route	Times of Administration					Duration of Treatment
			0800 1000	1200 1400	1600 1800	2000 2200	other time	
<u>Balneum Plus Cream</u>	<u>10pp</u>	<u>top</u>	<input checked="" type="checkbox"/>	<input checked="" type="checkbox"/>	<input type="checkbox"/>	<input type="checkbox"/>	<input type="checkbox"/>	<u>500 ml</u>
<u>Celebrex</u>	<u>10mg</u>	<u>po</u>	<input type="checkbox"/>	<input type="checkbox"/>	<input type="checkbox"/>	<input type="checkbox"/>	<input type="checkbox"/>	
<u>Hydrocortisone</u>	<u>25mg</u>	<u>po</u>	<input type="checkbox"/>	<input type="checkbox"/>	<input type="checkbox"/>	<input checked="" type="checkbox"/>	<input type="checkbox"/>	

Additional comments/reason for change of therapy/change of dose

Emovate Cream 2x day if needed. (30g)
for itch.

Doctor: [Signature] Signature: [Signature] Date: 23/2/10
 GMC No: 4041314 Page No:

(White Copy to G.P. Pink Copy to Medical)

LAT194

Scanned Document
 13-May-2026 LIZMC
 Additional:Scanned Document

Filename: igprda202605131431200.pdf
 Extension:.tif
 Pages:

NHS Confidential: Personal data about a patient

WISHAW GENERAL HOSPITAL
 50 Netherton Street
 WISHAW. ML2 0DP

Telephone - 01698 361100
 Facsimile - 01698 366418



NJW/AW/SR/8138603
 CHI No0209615214

Direct Dial 01698-366379
 E-Mail SandraRodgers@lanarkshire.scot.nhs.uk

Direct Dial 01698-366379

Department of Dermatology

Clinic 23rd February 2010
 Typed 27th March 2010

Mr I Mackay
 Consultant Plastic Surgeon
 Wishaw General Hospital
 WISHAW.

Dear Mr Mackay

JAMES HANEY 02.09.1961
9 COMMUNITY PLACE, BELLSHILL, ML4 2DG

Diagnosis Basal Cell Carcinoma ala nasi labial fold
 Generalised Pruritus on Back

Treatment Referral to Plastic Surgery for Excision of
 Large Basal Cell Carcinoma
 Balneum Plus Cream two to three times daily
 as needed for Back.
 Hydroxyzine 25mg at night for itch
 Eumovate Cream if needed as additive treatment for itch

Follow-up Referral to Plastic Surgeons for excision of BCC.

This patient was referred with a large basal cell carcinoma on the ala nasi labial fold. It had a classical appearance of a rodent ulcer. There were nor other lesions today. The patient is not on Aspirin or Warfarin and has no known allergies. I explained the diagnosis to the patient and I have also given him an information leaflet.

He also complained of itch on his back and treatment is as outlined above. There was no evidence of dermographism today, but I think he may benefit from the antihistamine.

Yours Sincerely

Dr Alvin [redacted]
 Specialist Registrar in Dermatology
 To Dr N J Wainwright
 c.c. Dr S Findlay, [redacted] Medical Centre, 2 Pollock Street Bellshill

TELL NORMAL	<input type="checkbox"/>
SCRIPT	<input type="checkbox"/>
SPEAK TO DR/NURSE	<input type="checkbox"/>
ATTEND	<input type="checkbox"/>
FILE	<input checked="" type="checkbox"/>

LAT100

Scanned Document
 13-May-2026 LIZMC
 Additional:Scanned Document

NHS Confidential: Personal data about a patient

From: oohfailedemail@lanarkshire.scot.nhs.uk
 Sent: 04 May 2010 01:00
 To: OOH62031@LANARKSHIRE.SCOT.NHS.UK
 Subject: Call #85064 04-May-2010

NHS Lanarkshire Primary Care Operating Division Date:04-May-2010 01:38

Call No.:85064 Call Category: Doctor Advice Priority: Within 1 Hour

Patients Name: James Raney
 Age: 02-Sep-1961 (Age: 48 years)

Current Location:9 Community Place

Bellshill
 Lanarkshire ML4 2DG
 Tel. No.: 01698 295507

Home Address: 9 Community Place

Bellshill
 Lanarkshire ML4 2DG
 Tel.No.: 01698 295507

Caller Origin: NHS24 Caller Name: Sharon
 Tel. No.: Gender: Male

Community Health Index: 0209615214

Temporary Resident:
 Surgery: Medical Centre (Park
 IGP: Park, D

Reported Condition:
 AND CALL TONIGHT PAIN WORSENING SAYS UNABLE TO TAKE MORE PAIN/PATIENT SAYS
 BREATHING ERRATICALLY (Other Clinical User) (Glasgow)

PATIENT CALLED SERVICE BACK DUE TO SEVERE DENTAL PAIN, PAIN ERRATIC, CRYING
 AND GETTING SEVERE HEADACHES WITH THE PAIN, PATIENT MAXED OUT ON PARACETAMOL
 UNTIL 10PM TOMORROW MORNING DUE TO PATIENT OVERMEDICATING, PATIENT ON BETA
 BLOCKERS & CITALAPRAM ADVISED THEY CANNOT TAKE ANYTHING ELSE, SPEAK TO T/L JUNE
 RANKINE SENT CALL TO HUB FOR DOCTOR TO CALL REGARDING PAIN RELIEF (De

NHS24 Ref.No.: 8752132 NHS24 : 04-May-2010 01:22

NHS24 Consultation Start: 04-May-2010 01:24
 NHS24 Consultation Complete: 04-May-2010 01:35
 NHS24 Outcome: Dx to phone patient within 1 Dx

NHS24 Clinical Summary:
 Clinical Summary created: 04-May-2010
 Nurse) (Cardonald) [04/05/2010 01:35:06]
 SEVERE HEADACHES ERRATIC SHAKEY & CRYING FOR TONIGHT AND STATES THIS IS DUE
 TO SEVERE DENTAL PAIN, PATIENT HAS TAKEN 12 PARACETAMOL IN 24 HOURS LAST DOSE
 WAS AT 10PM LAST NIGHT, PATIENT ON BETABLOCKER & CITALAPRAM UNABLE TO ADVISE
 ANYOTHER PAIN RELIEF ADVISED SPEAK TO DOCTOR

Advising Doctor: Feeney, James

History:
 severe dental pain overusing paracetamol-has taken 16tabs past 48hrs.advised

NHS Confidential: Personal data about a patient

can take brufen also--he will go to tesco.

Examination:

Diagnosis:

Treatment:

follow up message (Return To Sp Only if Condition Not Resolved)

Call No.: 85064 Patient Name: James Haney

THIRD PARTY COPY

Scanned Document
13-May-2026 LIZMC
Additional: Scanned Document

Filename: igprda202605131431150.pdf
Extension: .tif
Pages:

NHS Confidential: Personal data about a patient

WISHAW GENERAL HOSPITAL

50 Netherton Street
Wishaw
ML2 0DP
Telephone: 01698 361100
Fax: 01698 376671

Enquiries to: **Mr MacKay's Secretary**

Direct Line: 01698 366609
Jan [redacted] scot.nhs.uk



IRM/JK/8138603
CHI NUMBER: 0209615214

Clinic date: 17.5.10
Date typed: 18.5.10

Dr A [redacted]
Specialist Registrar in Dermatology
To Dr N J Wainwright
Level 1
Wishaw General Hospital

Dear Dr [redacted]

**JAMES HANEY 2.9.61 9 COMMUNITY PLACE BELLSHILL ML4 2DG
TELEPHONE NUMBER: 01698 295507**

Thank you for referring this gentleman who has a 1 - 2 cms diameter basal cell carcinoma on the left alar of his nose. I will arrange for this to be excised and reconstructed with a naso-labial flap as a day case under local anaesthetic.

Yours sincerely

Iain MacKay
Mr Iain R MacKay
CONSULTANT PLASTIC SURGEON

c.c. Dr S Findlay
[redacted] Medical Centre
2 Pollock Street
Bellshill
ML4 1QD

c.c. Nessie McLuckie, Plastic Surgery Secretary, Canniesburn Plastic Surgery,
Jubilee Building, Glasgow Royal Infirmary, Glasgow.

TELL NORMAL	<input checked="" type="checkbox"/>
SCRIPT	<input type="checkbox"/>
SPEAK TO DR/NURSE	<input type="checkbox"/>
ATTEND	<input type="checkbox"/>
FILE	<input checked="" type="checkbox"/>

**PLEASE SEND COPY OF PATHOLOGY TO:
JAN [redacted] PLASTIC SURGERY SECRETARY, LEVEL 1, WISHAW GENERAL
HOSPITAL**

LAT100

Scanned Document
13-May-2026 LIZMC
Additional:Scanned Document

Filename: igprda202605131431130.pdf
Extension:.tif
Pages:

NHS Confidential: Personal data about a patient

Acute Services Division
Canniesburn Plastic Surgery Unit
Jubilee Building
Glasgow Royal Infirmary
Glasgow G4 0SF



64393020E	
HANBY	M
JAMES	02/09/1961
9 COMMUNITY PLACE	
BELLSHILL	
LANARSHIRE	ML4 2DG
CHI-0209615214	

OPD - 0141 2115737 (Mon-Fri 8am-5pm)
Ward 49 - 0141 2115791 (Out with office hours)

Date: 18-06-10

Dear Doctor,
Your patient underwent a local anaesthetic procedure within the Canniesburn Plastic Surgery Unit today as follows:

excision lesion left alar with a local
flap reconstruction

An appointment with GP / OPD

For Suture Removal

On 7 days

Plastic Surgery follow up needed YES NO

At Mr Macay's clinic @

In 6 Weeks Months

TELL NORMAL	<input type="checkbox"/>
SCRIPT	<input type="checkbox"/>
SPEAK TO DR/NURSE	<input type="checkbox"/>
ATTEND	<input type="checkbox"/>
FILE	<input type="checkbox"/>

is required

Pathology report if applicable will follow when available.

Yours Sincerely,

Mr Romeo
P.P.R. Lewstey

Delivering better health
www.nhsggc.org.uk

MIS 161720-2

Scanned Document
13-May-2026 LIZMC
Additional:Scanned Document

NHS Confidential: [REDACTED]

Acute Services Division

Canniesburn Plastic Surgery Unit

Consultant : Mr I Mackay

The Jubilee Building
The Royal Infirmary
16 [REDACTED] Parade
GLASGOW G31 2ER
Switchboard : 0141 211 4000
Direct Line: 0141 211 5747
Fax: 0141 211 9356
E-mail address:
Ness.McLuckie@northglasgow.scot.nhs.uk

NHS
Greater Glasgow
and Clyde

Typed 09/07/2010
Our Ref IRM/MMH

Dr [REDACTED] Findlay
2 Pollock Street
Mossend
Bellshill
ML4 1QD

Dear Dr Findlay

James Haney - 02/09/1961 - CHI: 0209615214 - CRN: 64393020E
9 Community Place, Bellshill, Lanarkshire, ML4 2DG

ADMITTED 18.06.2010
DISCHARGED 18.06.2010
DIAGNOSIS 1-2 cms diameter basal cell carcinoma on the left alar of nose.
PROCEDURE Excision BCC l/alar of nose & reconstruction with nasolabial flap.

Follow up removal of sutures at Nurse Led Clinic on 25th June. Mr Mackay's Outpatient Clinic at Wishaw General Hospital in 6 week's time.

Kind regards
Yours sincerely


Mr [REDACTED] Mackay
Consultant Plastic Surgeon

TELL NORMAL	<input type="checkbox"/>
SCRIPT	<input type="checkbox"/>
SPEAK TO DR/NURSE	<input type="checkbox"/>
ATTEND	<input type="checkbox"/>
FILE	<input type="checkbox"/>

HANEY, James

Page 1 of 1

NHS Confidential: Personal data patient

PATHOLOGY DEPT - GLASGOW ROYAL INFIRMARY

Lab No.:R,10.0011968

CHI No. 0209615214

Name:HANEY JAMES

DOB/Age:02.09.61
Post code:ML4 2DG

Hosp.No(orPath.Comp.Ref.ZP): 64393020E

Consultant:MACKAY

Location:CAH WD 49

EXCISION BIOPSY LEFT ALAR NOSE

CLINICAL HISTORY

BCC marked with two long stitches one medial margin, other lateral margin.

Macro: A skin ellipse 20x18x9mm with a long stitch at 12 o'clock and short stitch at 9 o'clock.

Micro: Microscopy shows skin with a nodular basal cell carcinoma which has an infiltrative pattern at the invasive front of the tumour. The tumour is 2.1mm from the deep margin and 7mm from the 9 o'clock margin. There is perineural invasion. The lesion is completely excised.

JM

Dr H Pitchamuthu

This report has been authorised electronically by Dr Hema PITCHAMUTHU.

*Copy to Wisham
then file 20/6/10*

25 JUN 2010

Rep .Path.Dr Hema PITCHAMUTHU
Cons.Path.Dr Hema PITCHAMUTHUDate collected 18.06.10
Date received 18.06.10
Date reported 24.06.10

Page 1 of 1

Scanned Document
13-May-2026 LIZMC
Additional:Scanned DocumentFilename: igprda202605131431080.pdf
Extension:.tif
Pages:

NHS Confidential: Personal data about a patient

Acute Services Division

Canniesburn Plastic Surgery Unit

Consultant : Mr I Mackay

The Jubilee Building
The Royal Infirmary
16 Alexander Parade
GLASGOW G3 7ER
Switchboard : 0141 211 4000
Direct Line: 0141 211 5747
Fax: 0141 211 9356
E-mail address:
Ness.McLuckie@northglasgow.scot.nhs.uk



Not 62014

Typed 09/07/2010
Our Ref IRM/MH

21/6203

Dr Findlay
2 Pollock Street
Mossend
Bellshill
ML4 1QD

Dear Dr Findlay

James Haney - 02/09/1961 - CHI: 0209615214 - CRN: 64393020E
9 Community Place, Bellshill, Lanarkshire, ML4 2DG

ADMITTED 18.06.2010
DISCHARGED 18.06.2010
DIAGNOSIS 1-2 cms diameter basal cell carcinoma on the left alar of nose.
PROCEDURE Excision BCC l/alar of nose & reconstruction with nasolabial flap.

Follow up removal of sutures at Nurse Led Clinic on 25th June. Mr Mackay's Outpatient Clinic at Wishaw General Hospital in 6 week's time.

Kind regards
Yours sincerely

Mr Iain Mackay
Consultant Plastic Surgeon

16 JUL 2010

THIRD PARTY COPY

NHS Confidential: Personal data about a patient

PATHOLOGY DEPT - GLASGOW ROYAL INFIRMARY

Lab No.: R.10.0011968

CHI No. 0209615214

Name: HANEY JAMES

DOB/Age: 02.09.61
Post code: ML4 2DG

Hosp.No (or Path.Comp.Ref.ZP): 64393020E

Consultant: MACKAY

Location: CAH WD 49

EXCISION BIOPSY LEFT ALAR NOSE**CLINICAL HISTORY**

BCC marked with two long stitches one medial margin, other lateral margin.

Macro: A skin ellipse 20x18x9mm with a long stitch at 12 o'clock and short stitch at 9 o'clock.

Micro: Microscopy shows skin with a nodular basal cell carcinoma which has an infiltrative pattern at the invasive front of the tumour. The tumour is 2.1mm from the deep margin and 7mm from the 9 o'clock margin. There is perineural invasion. The lesion is completely excised.

JM

Dr H Pitchamuthu

This report has been authorised electronically by Dr Hema
PITCHAMUTHU:

*Copy to wishu
then file 25/6/10*

25 JUN 2010

Rep .Path.Dr Hema PITCHAMUTHU
Cons.Path.Dr Hema PITCHAMUTHUDate collected 18.06.10
Date received 18.06.10
Date reported 24.06.10

Page 1 of 1

Scanned Document
13-May-2026 LIZMC
Additional: Scanned Document

Filename: igprda202605131431050.pdf
Extension: .tif
Pages:

NHS Confidential: Personal data about a patient

WISHAW GENERAL HOSPITAL

50 Netherton Street
Wishaw
ML2 0DP
Telephone: 01698 361100
Fax: 01698 376671

Enquiries to: Mr MacKay's Secretary

Direct Line: 01698 366609
Jan [REDACTED]



IRM/JK/8138603
CHI NUMBER: 0209615214

Clinic date: 23.8.10
Date typed: 25.8.10

Dr S Findlay
[REDACTED] Medical Centre
2 Pollock Street
Bellshill
ML4 1QD

Dear Dr Findlay

JAMES HANEY 2.9.61 9 COMMUNITY PLACE, BELLSHILL ML4 2DG

I saw this gentleman back at my clinic. He had a large basal cell carcinoma of the left alar excised and reconstructed with a nasolabial flap. Histology is reported as showing complete excision. The flap is still a little swollen so I will arrange to see him once more in a year's time to see how it is settled.

Yours sincerely


Mr Iain R MacKay
CONSULTANT PLASTIC SURGEON

c.c. Dr A Wong
Specialist Registrar in Dermatology
To Dr N J Wainwright
Level 1
Wishaw General Hospital

TELL NORMAL	<input type="checkbox"/>
SCRIPT	<input type="checkbox"/>
SPEAK TO DR/NURSE	<input type="checkbox"/>
ATTEND	<input type="checkbox"/>
FILE	<input checked="" type="checkbox"/>

LAT100

Scanned Document
13-May-2026 LIZMC
Additional: Scanned Document

Filename: igprda202605131431030.pdf
Extension: .tif
Pages:

NHS Confidential: Personal data about a patient

Emergency Department
Wishaw General Hospital
50 Netherton Street
Wishaw ML2 0DP

Dr S Findlay
2 Pollock Street
Mossend
Bellshill
Lanarkshire
ML4 1QD

12 September 2010

Re: JAMES HANEY, 9 COMMUNITY PLACE, BELLSHILL, LANARKSHIRE, ML4 2DG
Date of Birth: 02.09.61 Hospital Number: 8138603 CHI Number: 0209615214

Your patient attended Wishaw General Hospital on the 12 SEP 2010 at 09:35 am.

The presenting complaint was: Unconscious Adult Was Assaulted 11 Pm Sat Seen At Mdx For Head Inj

Triage information: Nil

The following investigations were carried out: Nil

The A&E diagnosis was: Head - Minor Head Injury

The following treatment was given: Alcohol Screening Tool

At the conclusion of treatment the patient was: Discharged

Follow-up: None

Additional information: Nil

Yours sincerely,

██████ Rae

TELL NORMAL	<input checked="" type="checkbox"/>
SCRIPT	<input type="checkbox"/>
SPEAK TO DR/NURSE	<input type="checkbox"/>
ATTEND	<input type="checkbox"/>
FILE	<input checked="" type="checkbox"/>

Consultants

Scanned Document
13-May-2026 LIZMC
Additional:Scanned Document

Filename: igprda202605131431010.pdf
Extension:.tif
Pages:

NHS Confidential: Personal data about a patient

Emergency Department
Monklands Hospital
Monkscourt Ave
Airdrie ML6 0JS

Dr S Findley
2 Pollock Street
Mossend
Bellshill
Lanarkshire
ML4 1QD

13 September 2010

Re: JAMES HANEY, 9 COMMUNITY PLACE, BELLSHILL, LANARKSHIRE, ML4 2DG
Date of Birth: 02.09.61 Hospital Number: 8136603 CHI Number: 0209615214

Your patient attended Monklands Hospital on the 12 SEP 2010 at 01:39 am.

The presenting complaint was: **Assault (Facial Injuries)**

Triage Information: **Nil**

The following investigations were carried out: **Full Blood Count
Coagulation Screen
Urea And Electrolytes**

The A&F diagnosis was: **Head - Minor Head Injury - A**

The following treatment was given: **Advice**

At the conclusion of treatment the patient was: **Discharged**

Follow-up: **None**

Additional information: **Nil**

Yours sincerely,

 Gallacher

Consultants

TELL NORMAL	<input type="checkbox"/>
SCRIPT	<input type="checkbox"/>
SPEAK TO DR/NURSE	<input type="checkbox"/>
ATTEND	<input type="checkbox"/>
FILE	<input checked="" type="checkbox"/>

Scanned Document
13-May-2026 LIZMC
Additional:Scanned Document

NHS Confidential: Personal data about a patient

From: oohfailedemail@lanarkshire.scot.nhs.uk
Sent: 31 October 2010 01:00
To: OOH62031@LANARKSHIRE.SCOT.NHS.UK
Subject: Call #62346 30-Oct-2010

NHS Lanarkshire Primary Care Operating Division Date:30-Oct-2010 19:54

Call No.:62346 Call Category: Patient Trans Priority: Within 1 Hour

Patients Name: James Haney
 Age: 02-Sep-1961 (Age: 49 years)

Current Location: 9 Community Place

Bellshill
 Lanarkshire ML4 2DG
 Tel. No.: 01698 295507

Home Address: 9 Community Place

Bellshill
 Lanarkshire ML4 2DG
 Tel.No.: 01698 295507

Caller Origin: NHS24 Caller Name: [REDACTED]
 Tel. No.: Gender: Male

Community Health Index: 0209615214

Temporary Resident:
 Surgery: [REDACTED] Medical Centre (Park
 [GP: Park, D

Reported Condition:
 HEAD PAIN, WORSENER IN THE PAST 3 DAYS, PRODUCTIVE COUGH WITH GREEN PHLEGM,
 GIVEN ANTIBIOTICS LAST WEEK THOSE FINISHED, BLURRED VISION, BLOOD WHEN WIPING
 HIMSELF AFTER MOVING BOEELS 2 DAYS ((Non-Clinical User) (Cardonald))

PRIORITY CHANGED BY TL [REDACTED] ((Non-Clinical User) (Cardonald))

ADVISED NURSE WOULD CALL HER BACK WHEN AVAILABLE ((Non-Clinical User) (Glasgow))

NOT SUITABLE FOR ADVISE AND DISCHARGE. ((Non-Clinical User) (Cardonald))

CB COUGH 3 WEEKS SEE A/V

NHS24 Ref.No.: 9389775 NHS24 Date/Time: 30-Oct-2010 18:14

NHS24 Consultation Start: 30-Oct-2010 18:17
 NHS24 Consultation Complete: 30-Oct-2010 19:52
 NHS24 Outcome: Dr to phone patient within 1 Hr

NHS24 Clinical Summary:
 Clinical summary created: 30-Oct-2010
 [GP: Park, D] (Cardonald) [30/10/2010 19:52:22]
 COUGH FOR 3 WEEKS AND THROAT PAIN, LEG PAIN, PRODUCTIVE COUGH, BLOOD FROM BACK
 PASSAGE 2 DAYS, PCEC 4 HOURS, DISPUTED OUTCOME, GP TO CONTACT PT

Triage Nurse/Doctor: Triage Nurse (Non-Clinical User) (Cardonald)

NHS Confidential: Personal data about a patient

 History:

VIP not working, dw patient, cough sore throat 3/52, was treated with amoxicillin, gets headache everytime he coughs, green spit, does not suffer from asthma, copd, also fresh bleeding pr, hard stools, sounds comfortable on phone, not sob, no temp, no rash, needs seen as routine appointment, no transport

Examination:

Diagnosis:

cough induced cephalgia

Treatment:

pcec 4 hrs, needs pt transport, agreed to come to pcec

 Consulting Doctor: SYEEDA

History:

Worsening cough sx last 2/52 - completed course of amox 3/7 ago with no improvement of sx. Ongoing productive cough - green phelgm. Cough painful and causing headache.? Intermitt fever, non smoker. No hx of asthma. also been constipated last few days - passing hard stools/ painful and noticed fresh blood pr pmhx - depression dhx - venlafaxine/ propranolol.

Examination:

alert/ bright/ undistressed - coughing+++ p 92 - reg bp 141/ 88 o2 98% perla/ froem. rr 16/min. t 36.4 chest - creps left base. good air entry bilat hs norm. No signs of meningism/ photophobia

Diagnosis:

LRTI - cough cephalgia

Treatment:

Clarithromycin 500mg bd 7/7. Paracetamol/ brufen for headache. Fluids advice. Worsening statment
 Doctor SYEEDA

clarithromycin tablets 500mg
 (14) tablet(s)

TAKE ONE TABLET TWICE A DAY

 follow up message (Return To Gp Only If Condition Not Resolved)

Call No.: 62346 Patient Name: James Haney

Scanned Document
13-May-2026 LIZMC
Additional:Scanned Document

Filename: igprda202605131430560.pdf
Extension:.tif
Pages:

NHS Confidential: Personal data about a patient

Emergency Department
Wishaw General Hospital
50 Netherton Street
Wishaw ML2 0DP

Dr S Findlay
2 Pollock Street
Mossend
Bellshill
Lanarkshire
ML4 1QD

12 December 2010

Re: JAMES HANEY, 9 COMMUNITY PLACE, BELLSHILL, LANARKSHIRE, ML4 2DG
Date of Birth: 02.09.61 Hospital Number: 8138603 CHI Number: 0209615214

Your patient attended Wishaw General Hospital on the 12 DEC 2010 at 00:04 am.

The presenting complaint was: **Assault-Head And Small Laceration To Right Eye**

Triage information: **Nil**

The following investigations were carried out: **None**

The A&E diagnosis was: **Laceration - Eyebrow**

The following treatment was given: **Sutures X5**

At the conclusion of treatment the patient was: **Discharged**

Follow-up: **None**

Additional information: **None**

Yours sincerely,

[Redacted Signature]

Consultants

TELL NORMAL	<input checked="" type="checkbox"/>
SCRIPT	<input type="checkbox"/>
SPEAK TO DR/NURSE	<input type="checkbox"/>
ATTEND	<input type="checkbox"/>
FILE	<input checked="" type="checkbox"/>

THIRD PARTY COPY

NHS Confidential: Personal data about a patient

Lanarkshire Eye-Health Network Scheme 2 (LEN2)



Ophthalmic Assessment

Assessment Date: 8/1/11

Patient details (addressograph label)

CHI No:
 Hospital No: 8158603
 Name: JAMES HANNEY
 Address: 9 COMMUNITY PL
 BELLSHILL
 Date of birth: 2/9/61
 Tel No:

Optometrist details:

Name:
 Address:
 Tel No:
 GOC No:

GP Details:

Name: DR GADDIS
 Address: 2 BIRCH ST
 BELLSHILL
 Tel No:

Referral from: (please tick)
 Self Optometrist
 GP OOH A&E
 Internal: (specify)

Blood Pressure

Allergies

Yes - specify
 No

Current medication: Anti-Diplopia

Examination

Right Eye (tick appropriate box)		Left Eye (tick appropriate box)	
Visual Acuity (D) 6/5+2	<input checked="" type="checkbox"/> Aided <input type="checkbox"/> Unaided	Visual Acuity (D) 6/5+1	<input type="checkbox"/> Aided <input checked="" type="checkbox"/> Unaided
Visual Acuity (D)	<input type="checkbox"/> Pinhole	Visual Acuity (D)	<input type="checkbox"/> Pinhole
Visual Acuity (N)	<input type="checkbox"/> Aided <input type="checkbox"/> Unaided	Visual Acuity (N)	<input type="checkbox"/> Aided <input type="checkbox"/> Unaided
Tonometry 13	<input type="checkbox"/> Tonopen <input checked="" type="checkbox"/> GT	Tonometry 13	<input type="checkbox"/> Tonopen <input checked="" type="checkbox"/> GT
RAPD		RAPD	
Dilated		Dilated	

Investigations done: (tick all that apply)

Visual acuity Tonometry
 Bloods FFA OCT
 Eye irrigation Visual

Ishihara
 OCT

Clinical code:

Diagnosis: Normal Eye Exam. History of Migraine & Eye Pain
 Management: Educate SOS Signs for IOP. Refer to Ophthalmologist & Photophthalmologist.
 A.S.O.P.

Admission Discharged Follow up eye clinic - timescale:

Follow up Optometrist
 Signature: P.P. Dr. G. G. G.

Top copy Patients Notes 2nd copy Optometrist 3rd copy GP 4th copy Clinical Quality Service (for Audit purposes)

Filename: igprda202605131430530.pdf

Extension:.tif

Pages:

NHS Confidential: [REDACTED]

From: oohfailedemail@lanarkshire.scot.nhs.uk
 Sent: 09 January 2011 00:00
 To: OOH62031@LANARKSHIRE.SCOT.NHS.UK
 Subject: Call #92941 08-Jan-2011

NHS Lanarkshire Primary Care Operating Division Date:08-Jan-2011 18:02

Call No.:92941 Call Category: Home Visit Priority: Within 2 Hours

Patients Name: James Haney
 Age: 02-Sep-1961 (Age: 49 years)

Current Location:9 Community Place

Bellshill
 Lanarkshire ML4 2DG
 Tel. No.: 01698 295507

Home Address: 9 Community Place

Bellshill
 Lanarkshire ML4 2DG
 Tel.No.: 01698 295507

Caller Origin: NHS24 Caller Name: [REDACTED]
 Tel. No.: Gender: Male

Community Health Index: 0209615214

Temporary Resident:
 Surgery: [REDACTED] Medical Centre (Park
 |GP: Park, D

Reported Condition:
 PT HAS AND SORE THROAT, FLU SYMPTOMS FOR FEW DAYS, HEADACHE-SHARP/JAGGY PAIN
 AT EYES. ((Non-Clinical User) (Cardonald))

HEADACHE/CLAMMY TOUCH/SEE/AV [REDACTED]

NHS24 Ref.No.: 9697704 NHS24 Date: [REDACTED] 08-Jan-2011 17:45

NHS24 Consultation Starts: 08-Jan-2011 17:48
 NHS24 Consultation Complete: 08-Jan-2011 18:00
 NHS24 Outcome: Home Visit within 2 Hrs

NHS24 Clinical Summary:

Clinical summary created: 08-Jan-2011
 dvisor (Aberdeen) {08/01/2011 18:00:12}
 HEAD/ EYE PAIN FOR 24 HOURS AND C/O SHARP PAIN BEHIND LEFT [REDACTED] CONSTANTLY - &
 SHARP STINGING PAIN IN HEAD - VISION CLEAR - NO DIZZINESS, NO NAUSEA, FEVER,
 CLAMMY TO TOUCH, ORIENTATED, ALERT - INITIALLY PAIN ON RIGHT SIDE - HOLDING
 HEAD - COLD/ CONGESTION - DESCRIBES COLD/FLU SYMPTOMS FOR 2/7 -- IBUPROFEN NOT
 EFFECTIVE - POOR FLUID INTAKE -- HEAD INJURY 2/12 AGO - C/O ON/OFF HEAD PAINS
 SINCE INJURY -- HOME VISIT 2 HOURS

Consulting Doctor: GUTHRIE G

History:

flu likje for 2/52- cough and nasal cong and c/o severe pain left eye and h/a all
 day with photophobia-pmh-excision of lesion left nose- plastics this year-

NHS Confidential: Personal data about a patient

meds- see eca
Examination:
t 37.1,p88-bp 120/70- chest-clear- no sinus tenderness- acuity no snellen
chart- but no c/o blurring- left pupil constricted and irregular,photophobia++
and watering
Diagnosis:
most likely iritis??? glaucoma
Treatment:
d/w o/c ophthalmologist- will see in wd 5 hairmyres- no transport- ambulance
arranged-co-cod 30/500- 2 tabs stat

follow up message (Other)
ophthalmologist will see in wd 5 hairmyres

follow up message (Hairmyres ACUP [redacted] Session A & E)
Admitted to ward 5 Hairmyres Auth [redacted] Amb 2 hours ref 3621077

Call No.: 92941 Patient Name: James Hansy

THIRD PARTY COPY

Scanned Document
 13-May-2026 LIZMC
 Additional: Scanned Document

Filename: igprda202605131430500.pdf
 Extension: .tif
 Pages:

NHS Confidential: Personal data about a patient

Department of Biochemistry - Monklands Hospital
 Telephone 01236 712106/08

NHS Lanarkshire **CPA**

Surname HANEY	Forename James	CHI Number 0209615214	Date of birth 02 Sep 1961
Address 9 COMMUNITY PLACE BELLSHILL		Consultant / Practitioner Dr S. [REDACTED]	Specialist [REDACTED] Medical Centre 2 Pollock Street
Clinical details ITCH, RASH			

Total Prot.	74 g/l	(62-82)
Albumin	44 g/l	(36-52)
Globulin	30 g/l	(21-37)
Bilirubin	9 umol/l	(0-22)
AST	24 IU/L	(1-38)
ALT	20 IU/L	(0-50)
A.Phos.	101 IU/L	(30-130)
GGT	48 IU/L	(0-90)
LDH	L 202 IU/L	(250-500)

TELL NORMAL	<input checked="" type="checkbox"/>
SCRIPT	<input type="checkbox"/>
SPEAK TO DR/NURSE	<input type="checkbox"/>
ATTEND	<input type="checkbox"/>
FILE	<input type="checkbox"/>

TELL NORMAL	<input type="checkbox"/>
SCRIPT	<input type="checkbox"/>
SPEAK TO DR/NURSE	<input type="checkbox"/>
ATTEND	<input type="checkbox"/>
FILE	<input checked="" type="checkbox"/>

Specimen No. AQ630067	Specimen Type Serum	Date and Time Collected 12 Aug 2011 12:10	Date and Time Received 12 Aug 2011 15:10	Date and Time Printed 12 Aug 2011 18:07	Initialed by Auto.
---------------------------------	-------------------------------	---	--	---	------------------------------

THIRD PARTY COPY

Scanned Document
13-May-2026 LIZMC
Additional: Scanned Document

Filename: igprda202605131430480.pdf
Extension: .tif
Pages:

NHS Confidential: Personal data about a patient

WISHAW GENERAL HOSPITAL
50 Netherton Street
Wishaw
ML2 0DP
Telephone: 01698 361100
Fax: 01698 376671

Enquiries to: Mr MacKay's Secretary

Direct Line: 01698 366609



RC/JK
CHI NUMBER: 0209615214

Clinic date: 29.8.11
Date typed: 31.8.11

Dr S Findlay
Medical Centre
2 Pollock Street
Bellshill
ML4 1QD

TELL NORMAL	<input type="checkbox"/>
SCRIPT	<input type="checkbox"/>
SPEAK TO DR/NURSE	<input type="checkbox"/>
ATTEND	<input type="checkbox"/>
FILE	<input checked="" type="checkbox"/>

Dear Dr Findlay

JAMES HANEY 2.9.61 9 COMMUNITY PLACE BELLSHILL ML4 2DG

I reviewed this gentleman in the clinic today. The flap on his left nose remains bulky, cosmetically is unsatisfactory because it is elevated the upper end of his naso-labial crease. He also feels he has a bit of nostril tightness on this side and has some difficulty breathing. We have had a long chat with him today and feel that the best thing to do initially would be to perform a small crescending excision at the base of the flap to recreate the upper end of the naso-labial fold, a small ellipse in this direction should take away the vast bulk of the flap. It would also secure his nostril base laterally and should aid with his breathing as well. We will arrange to perform this under local anaesthetic in Wishaw General Hospital in the near future.

Yours sincerely

Specialist Registrar
To Mr Iain R. MacKay
CONSULTANT PLASTIC SURGEON

LAT100

Scanned Document
 13-May-2026 LIZMC
 Additional: Scanned Document

Filename: igprda202605131430460.pdf
 Extension: .tif
 Pages:

NHS Confidential: Personal data about a patient

MONKLANDS HOSPITAL
 Monkscourt Avenue
 Airdrie
 Lanarkshire
 ML6 0JS

NHS
 Lanarkshire

Department of Gastroenterology
 Consultants: Dr A T Prach, Dr M T Gangi & Dr Radhakrishnan
 IBD Nurse Specialist: [REDACTED] A M Scott, 01236 712036

Secretary to Dr Prach: [REDACTED] 01236 712424
 01236 712500
 Frances.Graham@lanarkshire.scot.nhs.uk

Our Ref: ATP/RC/0209615214

Clinic: 17 September 2011 - WLI
 Date: 19 October 2011

Dr S Campbell
 [REDACTED] Medical Centre
 2 Pollock Street
 Mossend
 Bellshill

TELE NORMAL	<input type="checkbox"/>
SCRIPT	<input type="checkbox"/>
SPEAK TO DR/NURSE	<input type="checkbox"/>
ATTEND	<input type="checkbox"/>
FILE	<input checked="" type="checkbox"/>

Dear Dr Campbell

James Haney (02.09.61), 9 Community Place, Bellshill

Thank you for referring this 50 year old man whom I saw at my waiting list initiative gastroenterology clinic today.

History: Mr Haney tells me that he has had fresh rectal bleeding at defecation for the past 4 months. He notices blood spattered in the toilet pan and also on the toilet paper. He describes a feeling of "pressure" at the anal margin and proctitis ani for the past 10 days. His weight has been steady and appetite is good. He was previously troubled with heartburn but this has since resolved. He is having no abdominal pain. His bowels are moving once or twice a day with formed stool. Mr Haney has had faecal urgency for 5 weeks and tenesmus for 4 months.

There is a past history of malignant melanoma for which he has had surgery on his face. The gentleman is on medication but cannot remember what this is. He has never smoked and drinks 24 units of alcohol per week.

Examination: Abdominal examination was entirely unremarkable.

Opinion: It very much sounds as if this man may have haemorrhoidal disease. He merits colonoscopy and this has been arranged. I shall let you know what transpires in due course.

Yours sincerely

Andy T. Prach

Dr A T Prach
 Consultant Physician & Gastroenterologist

LAT100

Scanned Document
13-May-2026 LIZMC
Additional: Scanned Document

Filename: igprda202605131430440.pdf
Extension: .tif
Pages:

NHS Confidential: Personal data about a patient

WISHAW GENERAL HOSPITAL

WISHAW GENERAL HOSPITAL
50 NETHERTON STREET
WISHAW
ML2 0DP
Telephone: 01698-361100

0209615214
02/09/1961 M
HONEY James
9 Community Place
Bellish Hill
Lanarkshire ML4 2DG

Date 24/05/11

Dr.

Dear Dr. FINLAY

Your patient JAMES HONEY of

attended the Day Bed Unit today where EXCISION OF X.S. TISSUE LEFT
NASAL ALAR FOLLOWING LOCAL FLAP
RECONSTRUCTION was carried out

Where appropriate, results of a pathological examination of tissue removed will be reported at a later date.

Findings EXCESS TISSUE LEFT NASAL ALAR
RESULTING IN COSMETIC + FUNCTIONAL ISSUES

Recommended Treatment

TISSUE SURGICALLY EXCISED

Follow-up

REMOVAL OF SUTURES 5 DAYS
RE CLINIC 2-3 MONTHS

Yours Sincerely,

D. SULLIVAN STK FOR PLASTIC SURGERY

for Mr. MACKAY

TELL NORMAL	<input type="checkbox"/>
SCRIPT	<input type="checkbox"/>
SPEAK TO DR/NURSE	<input type="checkbox"/>
ATTEND	<input type="checkbox"/>
FILE	<input checked="" type="checkbox"/>

FORM C

No. 0601

Distribution: White - G.P. Pink - C/S Yellow - Ref. Doctor Blue - Audit

Wishaw (Healthcare) 05911423236 11/07/06

Scanned Document
13-May-2026 LIZMC
Additional:Scanned Document

Filename: igprda202605131430430.pdf
Extension:.tif
Pages:

NHS Confidential: Personal data about a patient

WISHAW GENERAL HOSPITAL

50 Netherton Street
Wishaw
ML2 0DP
Telephone: 01698 361100
Fax: 01698 376671

Enquiries to: Mr MacKay's Secretary
☎: 01698 366609
✉: Jan [redacted]@scot.nhs.uk



NO'S/JK
CHI NUMBER: 0209615214

Minor Operation: 24.10.11
Typed : 27.10.11

Dr S Findlay
[redacted] Medical Centre
2 Pollock Street
Bellshill
ML4 1QD

Dear Dr Findlay

JAMES HANEY 2.9.61 9 COMMUNITY PLACE BELLSHILL ML4 2DG

Your patient attended the Outpatient department today for excision of excess tissue left nasal alar following local flap reconstruction. This was carried out under local anaesthetic in the outpatient department.

Patient has been advised to attend your surgery in 5 days time for excision of sutures and wound review.

We shall review this patient again in the Plastic Surgery outpatient clinic in 2 – 3 months.

Yours sincerely


Niamh O'Sullivan
Specialist Registrar
To Mr Iain R MacKay
CONSULTANT PLASTIC SURGEON

TELL NORMAL	<input type="checkbox"/>
SCRIPT	<input type="checkbox"/>
SPEAK TO NURSE	<input type="checkbox"/>
ATTEND	<input type="checkbox"/>
FILE	<input checked="" type="checkbox"/>

LAT100

Scanned Document
 13-May-2026 LIZMC
 Additional: Scanned Document

Filename: igprda202605131430410.pdf
 Extension: .tif
 Pages:

NHS Confidential: [REDACTED]

copy



**Endoscopy Unit, Monklands Hospital
 SIGMOIDOSCOPY REPORT**

Name:	James HANEY, 02/09/1961 (M)	Address:	9 Community Place Bellshill Lanarkshire ML4 2DG
CHI No:	0209615214		
Case note no.:	0209615214		
GP:	Dr S Campbell [REDACTED] Medical Centre 2 Pollock Street Mossend Bellshill ML4 1QD	Priority:	Elective
		Status:	Outpatient/NHS
		Hospital:	Monklands Hospital
		Referring Cons:	Dr A Prach (Monklands physicians)
		Procedure date:	9th November 2011

Indications
 Dripping of blood - frequently rectal bleeding.

Report
 Bowel preparation with Fleet was poor.
 A digital rectal examination was performed.
 The sigmoidoscope was inserted via the anus to the distal sigmoid, insertion limited by inadequate bowel preparation.
 The rest of the examination to the limit of insertion was normal.

Diagnosis
 (Haemorrhoids) ✓

Follow-up
 Awaiting pathology results. Return to the Referring Physician.

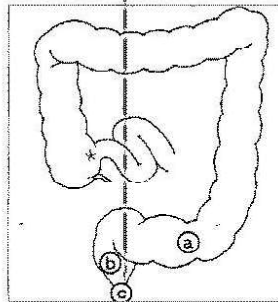
Advice/comments
 Note: This patient says that he had taken two Moveprep, but had no results. Hence I have proceeded for a flexible sigmoidoscopy with phosphate enema. This patient already had a full negative colonoscopy two years ago. In view of rectal bleeding, We have banded two haemorrhoids.

Dr S Radhakrishnan
 Consultant Gastroenterologist

Consultant/Endoscopist
 List consultant: Dr S Radhakrishnan
 Endoscopist No1: Dr S Radhakrishnan
 Endoscopist No2: [REDACTED] L Bethel
 Nurses: SN P A Hill
 SN E McAuley

Instruments
 495
 Disposable forceps

Premedication
 No medication given



a: Proximal sigmoid
 b: Rectum
 c: Anal margin

Specimens taken
 Biopsy (x2 site a and x1 site b)

TELL NORMAL	<input type="checkbox"/>
SCRIPT	<input type="checkbox"/>
SPEAK TO DR/NURSE	<input type="checkbox"/>
ATTEND	<input type="checkbox"/>
FILE	<input type="checkbox"/>

Scanned Document
 13-May-2026 LIZMC
 Additional: Scanned Document

Filename: igprda202605131430390.pdf
 Extension: .tif
 Pages:

NHS Confidential: Personal data about a patient

Monklands Hospital
 Monkscourt Avenue
 AIRDRIE
 ML6 0JS

NHS
 Lanarkshire

Department of Gastroenterology
 Consultants: Dr A T Prach, Dr M T Gangi, Dr S Radhakrishnan

Enquiries to: [REDACTED] Secretary to Dr Prach
 Direct Dial: 01236 712424
 Fax No: 01236 712500

Our Ref: ATP/ML
 CHI: 0209615214
 Clinic: 29.11.2011
 Typed: 14.01.2012

TELL NORMAL	<input type="checkbox"/>
SCRIPT	<input type="checkbox"/>
SPEAK TO DR/NURSE	<input checked="" type="checkbox"/>
ATTEND	<input type="checkbox"/>
FILE	<input checked="" type="checkbox"/>

Dr S [REDACTED]
 Medical Centre
 2 Pollock Street
 Mossend
 BELLSHILL

Dear Dr [REDACTED]

JAMES HAINES (02.09.61) 9 COMMUNITY PLACE BELLSHILL ML4 2DG

Mr Haines attended for planned colonoscopy on the 9th of November 2011 but instead had a flexible sigmoidoscopy carried out because he did not have a good result with Moveprep for bowel preparation. Mr Haines underwent flexible sigmoidoscopy following phosphate enema bowel prep with the instrument being advanced to the distal sigmoid colon. The examination was unremarkable apart from the finding of 2 haemorrhoids which were banded. Biopsies taken from the sigmoid colon were normal but there was a single small focus of active cryptitis in the rectal biopsy. The significance of this is unclear and could, for example, be induced by the bowel preparation itself.

I shall arrange for this man to be reviewed at my clinic in due course.

Yours sincerely

Andrew T. Prach

Dr AT Prach
 Consultant Gastroenterologist

LAT100

Scanned Document
13-May-2026 LIZMC
Additional: Scanned Document

Filename: igprda202605131430370.pdf
Extension: .tif
Pages:

NHS Confidential: Personal data about a patient

WISHAW GENERAL HOSPITAL
50 Netherton Street
Wishaw
ML2 0DP
Telephone: 01698 361100
Fax: 01698 376671

Enquiries to: Mr MacKay's Secretary
Direct Line: 01698 366609
Jan.Kidd@lanarkshire.scot.nhs.uk



IRM/JK
CHI NUMBER: 0209615214

Clinic date: 23.1.12
Date typed: 24.1.12

Dr S Findlay
Medical Centre
2 Pollock Street
Bellshill
ML4 1QD

Dear Dr Findlay

JAMES HANEY 2.9.61 9 COMMUNITY PLACE BELLSHILL ML4 2DG

I saw this gentleman back at my clinic following his revision of a naso-labial flap, which had been used to reconstruct the left alar of his nose following excision of a basal cell carcinoma in 2010. This looked better and has improved his breathing. The small lesion in the excised tissue was reported as sebaceous hyperplasia. I have now discharged him from my clinic.

Yours sincerely

Mr Iain R MacKay
CONSULTANT PLASTIC SURGEON

TELL NORMAL	<input checked="" type="checkbox"/>
SCRIPT	<input type="checkbox"/>
CON. NURSE	<input type="checkbox"/>
AT END	<input type="checkbox"/>
FILE	<input checked="" type="checkbox"/>

LAT100

Scanned Document
 13-May-2026 LIZMC
 Additional:Scanned Document

Filename: igprda202605131430350.pdf
 Extension:.tif
 Pages:

NHS Confidential: Personal data about a patient

NHS Lanarkshire
www.nhslanarkshire.org.uk

Monklands Hospital
 Monkscourt Avenue
 ML6 0JS
 Tel 01236 712424



Dr S Campbell
 [REDACTED] Medical Centre
 2 Pollock Street
 Mossend
 Bellshill
 ML4 1QD

Consultant: Dr Reza Esfahani on behalf of Dr.Prach
 Date Dictated: 24/02/2012
 Date Typed: 04/03/2012
 Ref: 59422
 Letter Ref: RE/ATP/ML
 Clinic Date: 24/02/2012
 CHI Barcode:



Dear [REDACTED]

Patient Name: James Haney
 Patient date of birth: 02/09/1961
 Patient Address: 9 Community Place, Bellshill, ML4 2DG

Diagnosis: 1. Haemorrhoids

I reviewed this gentleman at the Gastroenterology Clinic on behalf of Dr Prach today. His symptom of PR bleeding has settled and only very occasionally has some following flexible sigmoidoscopy and the banding of 2 piles. He is quite pleased with what he received. I also noted that previously in 2009 he had a colonoscopy and he told me they managed to go around his entire bowel and everything was normal. The skin rash on his face was basal carcinoma rather than malignant melanoma. I am quite happy to discharge him back to your care but would be happy to see him again if any new problems arise.

Yours sincerely

Dr R Esfahani
 GPWSI in Gastroenterology
 MD, MRCP, MRCP

Authorised on 09/03/2012 12:14:57 by Reza Esfahani.

TELL NORMAL	<input type="checkbox"/>
SCRIPT	<input type="checkbox"/>
SPEAK TO DR/NURSE	<input type="checkbox"/>
ATTEND	<input type="checkbox"/>
FILE	<input type="checkbox"/>

Scanned Document
 13-May-2026 LIZMC
 Additional:Scanned Document

Filename: igprda202605131430330.pdf
 Extension:.tif
 Pages:

NHS Confidential. Personal data about a patient

Department of Biochemistry - Monklands Hospital

Telephone 01236 712106/08

NHS Lanarkshire **IPA**
INTEGRATED PATIENT ACCESS
SINCE 01/01/10

Surname HANEY	Forename James	CHI Number 0209615214	Date of birth 02 Sep 1961
Address 9 COMMUNITY PLACE BELLSHILL		Consultant/Physician Dr S. [REDACTED]	Specialist [REDACTED] Medical Centre 2 Pollock Street

Clinical sheet:
PERISTENT ALL OVER BODY ITCH SWALLOWING PROBLEMS

Sodium	141 mmol/l	(135-145)	GGT	33 IU/L	(0-90)
Potassium	4.5 mmol/l	(3.5-5.0)	LDH	264 IU/L	(230-500)
Chloride	104 mmol/l	(95-105)	TSH	1.55 mIU/L	(0.20-5.00)
Bicarbonate	25 mmol/l	(21-28)	Free T4	15.5 pmol/l	(9-21)
Urea	4.5 mmol/l	(2.5-7.5)			
Creatinine	94 umol/l	(60-120)			
Estimated GFR	Greater than 99ml/min/1.73m ²				
Total Prot.	74 g/l	(62-82)			
Albumin	45 g/l	(34-52)			
Globulin	29 g/l	(21-37)			
Bilirubin	8 umol/l	(0-22)			
AST	24 IU/L	(1-38)			
ALT	18 IU/L	(0-50)			
A.Phos.	67 IU/L	(30-120)			



Laboratory Comment
 [TFT REQUESTED; NO THERAPY] Please note change in normal range for B12, Folate and Ferritin introduced 27.07.2011.

Specimen No. AR222535	Specimen Type Serum	Date and Time Collected 27 Jul 2012 11:18	Date and Time Received 27 Jul 2012 15:21	Date and Time Printed 27 Jul 2012 21:18	Initiated by Auto.
---------------------------------	-------------------------------	---	--	---	------------------------------

Scanned Document
 13-May-2026 LIZMC
 Additional: Scanned Document

Filename: igprda202605131430310.pdf
 Extension: .tif
 Pages:

NHS Confidential: Personal data about a patient

		Department of Biochemistry - Monklands Hospital Telephone 01236 712106/08			
Surname	Forename	CHI Number	Date of birth	Sex	
HANEY	James	0209615214	02 Sep 1961	M	
Address		Consultant / Practitioner	Referral Source		
9 COMMUNITY PLACE BELLSHILL		Dr S. [REDACTED]	[REDACTED] Medical Centre 2 Pollock Street		
Clinical Details					
PERISTENT ALL OVER BODY ITCH SWALLOWING PROBLEMS					
CEA (Roche)	2.8	ug/l		(0-5.0)
Serum B12	576	ng/l		(190-900)
Serum Ferritin	48	ng/ml		(30-400)
Serum Folate	7.8	ng/ml		(4.6-18.7)

Laboratory Comment

Turnour markers should not be used to screen, diagnose or exclude malignancy. Turnour markers analysed using the Roche Modular E170. Please note change in normal range for B12, Folate and Ferritin introduced 27.07.2011. Serum B12 assays may not simply reflect body stores. Iron deficiency can exist with normal ferritin levels.

Specimen No	Specimen Type	Date and Time Collected	Date and Time Received	Date and Time Printed	Authorised by
AR222535	Serum	27 Jul 2012 11:18	27 Jul 2012 15:21	28 Jul 2012 09:15	Ian Godber

Scanned Document
 13-May-2026 LIZMC
 Additional: Scanned Document

Filename: igprda202605131430280.pdf
 Extension: .tif
 Pages:

NHS Confidential: Personal data about a patient

NHS Department of Haematology - Monklands Hospital **CPA**
 Lanarkshire Telephone 01236 712103
 Summary: *Surname* HANEY *Forename* James *UIN Number* 0209615214 *Date of birth* 02 Sep 1961 *Sex* M
Address: 9 COMMUNITY PLACE BELLSHILL *Consultant / Practitioner* Dr S. [REDACTED] *Specialist Centre* [REDACTED] Medical Centre 2 Pollock Street

Clinical details:
 PERSISTENT ALL OVER BODY ITCH SWALLOWING PROBLEMS

Haemoglobin	14.0 g/dL	(13.5-18.0)	Platelets	248	x10 ⁹ /L	(150-450)
Red Cell Count	4.67 x10 ¹² /L	(4.5-6.5)	White Blood Count	4.5	x10 ⁹ /L	(4-12)
Haematocrit	0.416 L/L	(0.42-0.54)	Neutrophils	2.6	x10 ⁹ /L	(2.0-8.0)
MCV	89.1 fL	(80-100)	Lymphocytes	1.3	x10 ⁹ /L	(0.8-4.4)
MCH	30.0 pg	(27-32)	Monocytes	0.4	x10 ⁹ /L	(0-0.8)
MCHC	33.7 g/dL	(30.0-36.0)	Eosinophils	0.2	x10 ⁹ /L	(0-0.4)
ESR	1 mm/hr	(0-30)	Basophils	0.0	x10 ⁹ /L	(0-0.3)

Sequence No	Sequence Type	Date and Time Collected	Date and Time Received	Date and Time Printed	Actioned by
CR222535	Blood	27 Jul 2012 11:18	27 Jul 2012 15:21	27 Jul 2012 19:25	Auto.

Scanned Document
13-May-2026 LIZMC
Additional: Scanned Document

Filename: igprda202605131430250.pdf
Extension: .tif
Pages:

NHS Confidential: Personal data about a patient

NHS Department of Microbiology - Monklands Hospital **CPA**
Lanarkshire Telephone 01236 712120

Surname HANEY	Forename James	DOB Number 0209615214	Date of Birth 02 Sep 1961	Sex M
Address 9 COMMUNITY PLACE BELLSHILL		Consultant / Practitioner Dr S. DHILLON	Specialist Practitioner Bruce Medical Centre 2 Pollock Street	
Client or Health				
HELICOBACTER PYLORI TEST				
POSITIVE				

Script
H. pylori eradication

Specimen No.	Specimen Type	Date and Time Collected	Date and Time Received	Date and Time Printed	Authorised By
GR008143	VENOUS BLOOD	27 Jul 2012	27 Jul 2012 16:10	28 Jul 2012 11:23	Stark

THIRD PARTY COPY

NHS Confidential: Personal data about a patient

Page 1 of 2

James HANEY 02/09/1961 Male (Unknown) (Details)

Sample Details

Blood

Description: Blood Date/Time Sampled: 27/07/2012 11:18 Date/Time Tested:
 Laboratory Id: CR222535 Date/Time Received: 27/07/2012 15:21 Biohazard Alert:

Full blood count - FBC

Code(s)	Description	Value	Normal Range	Comments
423..	Haemoglobin estimation	14.0 g/dL	13.5 - 18.0	
42P..	Platelet count	248 x10 ⁹ /L	150 - 450	
42H..	Total white cell count	4.5 x10 ⁹ /L	4 - 11	
42J..	Neutrophil count	2.6 x10 ⁹ /L	2.0 - 8.0	
42M..	Lymphocyte count	1.3 x10 ⁹ /L	0.8 - 4.4	
42N..	Monocyte count	0.4 x10 ⁹ /L	0 - 0.8	
42K..	Eosinophil count	0.2 x10 ⁹ /L	0 - 0.4	
42L..	Basophil count	0 x10 ⁹ /L	0 - 0.3	
426..	"Red blood count" = Red blood cell (RBC) count	4.67 x10 ¹² /L	4.5 - 6.5	
LO 4258.	Haematocrit	0.416 L/L	0.42 - 0.54	
42A..	Mean corpuscular volume (MCV)	89.1 fl	80 - 100	
428..	Mean corpusc. haemoglobin(MCH)	30.0 pg	27 - 32	
429..	Mean corpusc. Hb. conc. (MCHC)	33.7 g/dL	30.0 - 36.0	

Code(s)	Description	Value	Normal Range	Comments
42B6.	Erythrocyte sedimentation rate	1 mm/hr	1 - 30	

Patient Details

Name James HANEY
 Address Current
 Type
 Address 9 COMMUNITY PLACE
 BELLSHILL
 LANARKSHIRE
 ML4 2DG
 Date of Birth 02/09/1961
 Sex Male
 Marital Unknown
 Status
 Registered S.
 Gp
 Practice (62031) MEDICAL CENTRE
 62031
 HB of Res.

File sd

Identifiers

CRN	8139461
REQ	8138603
CHI	0209615214
REQ	0209615214
NHS	PCXX/54
CHI	0209615214

Clinical Data REQUESTOR**PERISTENT ALL OVER BODY ITCH SWALLOWING PROBLEMS

file://O:\PROGRAM\temp\EB.HTML

02/08/2012

NH&S Confidential: Personal data about a patient

Page 1 of 3

James HANEY 02/09/1961 Male (Unknown) (Details)

Sample Details

Serum

Description: Serum Date/Time Sampled: 27/07/2012 11:18 Date/Time Tested:
 Laboratory Id: AR222535 Date/Time Received: 27/07/2012 15:21 Biohazard Alert:
 Requester: Please note change in normal range for B12, Folate and
 Comments: Ferritin introduced 27.07.2011.

Serum electrolytes

Code(s)	Description	Value	Normal Range	Comments
4415.	Serum sodium	141 mmol/l	135 - 145	
4414.	Serum potassium	4.5 mmol/l	3.5 - 5.0	
4416.	Serum chloride	104 mmol/l	95 - 105	
4417.	Serum bicarbonate	25 mmol/l	21 - 28	
4419.	Serum urea level	4.5 mmol/l	2.5 - 7.5	
4413.	Serum creatinine	94 umol/l	60 - 120	

Liver function tests

Code(s)	Description	Value	Normal Range	Comments
44GB.	Serum alanine aminotransferase level	18 IU/l	0 - 50	
44F.	"Serum Alkaline phosphatase" = Serum alkaline phosphatase	87 IU/l	30 - 120	
44E.	"Serum Bilirubin" = Serum bilirubin level	8 umol/l	0 - 22	

Code(s)	Description	Value	Normal Range	Comments
44M4.	Serum albumin	45 g/l	36 - 52	

Serum TSH level

Comments: [TFT REQUESTED: NO THERAPY]

Code(s)	Description	Value	Normal Range	Comments
442W.	Serum TSH level	1.55 mIU/l	0.20 - 5.00	

Code(s)	Description	Value	Normal Range	Comments
442V.	Serum free T4 level	15.5 pmol/l	9 - 21	

AST serum level

Code(s)	Description	Value	Normal Range	Comments
44B5.	"Serum AST" = AST - aspartate transam.(SGOT)	24 IU/L	1 - 38	

Serum LDH level

Code(s)	Description	Value	Normal Range	Comments
44HF.	Serum lactate dehydrogenase level	264 IU/L	230 - 500	

Code(s)	Description	Value	Normal Range	Comments
44G9.	"Serum Gamma GT" = Serum gamma-glutamyl transferase level	33 IU/L	0 - 90	

file://O:\PROGRAM\temp\F6.HTML

02/08/2012

NHS Confidential: Personal data about a patient

Page 2 of 3

44M3. Serum total protein	74 g/l	62 - 82
44M5. Serum globulin	29 g/l	21 - 37
451E. "Estimated GFR" = GFR calculated abbreviated MDRD	Greater than 59ml/min/1.73m ²	

Serum vitamin B12

Comments: Serum B12 assays may not simply reflect body stores.

Code(s)	Description	Value	Normal Range	Comments
42T.	Serum vitamin B12	576 ng/L	190 - 900	
42U5.	Serum folate	7.8 ng/ml	4.6 - 18.7	

Serum ferritin

Comments: Iron deficiency can exist with normal ferritin levels.

Code(s)	Description	Value	Normal Range	Comments
42R4.	Serum ferritin	48 ng/ml	30 - 400	

Carcinoembryonic antigen level

Comments: Tumour markers should not be used to screen, diagnose or exclude malignancy. Tumour markers analysed using the Roche Modular E170.

Code(s)	Description	Value	Normal Range	Comments
44a0.	Carcinoembryonic antigen level	2.8 ug/l	0 - 5.0	

Patient Details

Name James HANEY
 Address Type Current
 Address 9 COMMUNITY PLACE
 BELLSHILL
 LANARKSHIRE
 ML4 2DG
 Date of Birth 02/09/1961
 Sex Male
 Marital Status Unknown
 Registered Gp [REDACTED]
 Practice (62031) [REDACTED] Medical Centre
 HB of Res. [REDACTED]

Identifiers

CRN 8139461
 REQ 8138603
 NHS PCXX/254
 CHI 0209615214
 CHI 0209615214
 REQ 0209615214

file:///O:\PROGRAM\temp\F6.HTML

02/08/2012

Scanned Document
13-May-2026 LIZMC
Additional: Scanned Document

Filename: igprda202605131430180.pdf
Extension: .tif
Pages:

NHS Confidential: Personal data about a patient


NHS Lanarkshire
www.nhslanarkshire.org.uk

Wishaw General Hospital
50 Netherton Street
ML2 0DP



James Haney
9 Community Place
Bellshill
ML4 2DG

Consultant:
Date Dictated: 12/10/2012
Date Typed: 15/10/2012
Ref: 226994
Letter Ref: GC
CHI Barcode:



Dear James

Patient Name: James Haney
Patient date of birth: 02/09/1961
Patient Address: 9 Community Place, Bellshill, ML4 2DG

You were due to attend for endoscopy but have failed to do so. I will leave your further care in the hands of your GP. If there was some reason that you were unable to make it and you do wish to have the telescope test if you can let your GP know who can get back in touch with us to arrange this.

Kind regards.

Yours sincerely

Mr Segun Komolafe
Locum Consultant Surgeon

Authorised on 17/10/2012 17:55:46 by Segun Komolafe.

(P) Dr DJ Park
Medical Centre
2 Pollock Street
Mossend
Bellshill
ML4 1QD

TELL NORMAL	<input type="checkbox"/>
SCRIPT	<input type="checkbox"/>
SPEAK TO CLINICSE	<input type="checkbox"/>
ATTEND	<input type="checkbox"/>
FILE	<input checked="" type="checkbox"/>

THIRD PARTY COPY

Scanned Document
 13-May-2026 LIZMC
 Additional: Scanned Document

Filename: igprda202605131430170.pdf
 Extension: .tif
 Pages:

NHS Confidential: Personal data about a patient



NHS Lanarkshire Clinical Laboratories
 Microbiology, Monklands - 01236712121



<i>Patient ID Number</i> 0209615214	<i>Surname</i> HANEY	<i>Forename</i> JAMES	<i>Date of Birth</i> 02/09/1961	<i>Sex</i> Male	<i>Lab Number</i> 130153095
<i>Requesting Clinician</i> Dr. S [REDACTED]	<i>Requesting Location</i> [REDACTED] Medical Centre	<i>Copy to Address</i>			
<i>Clinical History</i>					

Specimen: MSU *Anatomical Site:*

Microscopy (Automated)

White Blood Cells	4	/uL (0-100)
Red Blood Cells	2	/uL (0-40)

Negative by Flow Cytometry. Culture is NOT indicated

<i>Specimen Collected</i> 20/02/2013 09:40	<i>Specimen Receipt</i> 20/02/2013 15:08	<i>Reported</i> 20/02/2013 15:30	<i>Reprinted</i>	<i>Last Authorised by</i> LIMS	<i>Page 1 of 1</i>
---	---	-------------------------------------	------------------	-----------------------------------	--------------------

THIRD PARTY COPY

NHS Confidential: Personal data about a patient

Date: 19/08/2013 Time: 13:35 To: [REDACTED] 62031-1 BELLSHILL @ ,01696740363
 Page: 001

NHS 24 FAX REPORT

NHS 24 ID:	Call ID: 1349632	Site:	Glasgow
CHI #:	0209615214	Center Name:	JAMES
Surname:	HANEY	Date/Time Call Received:	19/08/2013 13:24
Forename:	JAMES	Date Call Completed:	
DOB:	02/09/1961	Time Call Completed:	
Gender:	Male	Call Priority:	CSO
Address:	9 Community Place	Call Reason:	CHEST PAIN 1/7 SEE AV
		Current Location:	9 Community Place
			Bellshill
			Lanarkshire/ML4 2DG
PH NO:	[REDACTED] 2DG 01696740363 (Home)	Special Directions:	Front Door
		Current PH NO:	01696740363 (Home)
Care Provider:	PARK, D	Provider Details:	2 PDLLOCK ST AGSSEND BELLSHILL ML4 1QD Scotland

Temporary Resident: No

Referred To:

Recommended Action:

CLINICAL SUMMARY

CHEST PAIN FOR SINCE LAST NIGHT INTERMITTENTLY AND WORSE TODAY. GRIPPING PAIN ACROSS CHEST. FEELS SOB, COLOUR PALE, VOMITED. ALSO SUFFERS FROM ACID REFLUX BUT THIS SEEMS DIFFERENT. 999 AMBULANCE

MEDICAL HISTORY

MEDICAL PROBLEMS
 [REDACTED] FROM NSGE - 2010, DEPRESSION

MEDICATIONS

AS PER ECS

ALLERGIES

NONE

Referred Clinical Notes:

T:
 P:
 R:
 BP: /

Print Name:

Signature:

THIRD PARTY COPY

Scanned Document
 13-May-2026 LIZMC
 Additional:Scanned Document

Filename: igprda202605131430130.pdf
 Extension:.tif
 Pages:

NHS Confidential: Personal data about a patient



NHS Lanarkshire Clinical Laboratories
 Haematology, Monklands - 01236712104



Patient ID Number 0209615214	Surname HANEY	Forename JAMES	Date of Birth 02/09/1961	Sex Male	Lab Number 133961143
Requesting Clinician Dr. S	Requesting Location: Medical Centre	Copy to Address			

Clinical History
 STOMACH CRAMP TFT no therapy.

Results relate to blood unless otherwise stated

Hb	13.5	g/dL	(13.5-18.0)	WBC	6.5	$\times 10^9/L$	(4.0-11.0)
PLT	239	$\times 10^9/L$	(140-450)	Neutrophils	4.5	$\times 10^9/L$	(2.0-7.5)
MCV	88.3	fL	(80.0-100.0)	Lymphocytes	1.2	$\times 10^9/L$	(1.0-4.0)
RBC	4.43 L	$\times 10^{12}/L$	(4.50-6.50)	Monocytes	0.5	$\times 10^9/L$	(0.2-0.8)
HCT	0.391 L	L/L	(0.400-0.540)	Eosinophils	0.2	$\times 10^9/L$	(0.0-0.4)
MCH	30.5	pg	(27.0-32.0)	Basophils	0.0	$\times 10^9/L$	(0.0-0.1)
MCHC	34.5	g/dL	(32.0-36.0)				
RDW	13.6	%	(11.0-16.0)				
ESR	7	mm/hr	(1-30)				

Specimen Collected 09/10/2013 12:13	Specimen Receipt 09/10/2013 17:08	Reported 10/10/2013 15:30	Reprinted	Last Authorised by LIMS	Page 1 of 1
---	---	-------------------------------------	------------------	-----------------------------------	--------------------

Scanned Document
 13-May-2026 LIZMC
 Additional:Scanned Document

Filename: igprda202605131430120.pdf
 Extension:.tif
 Pages:

NHS Confidential: Personal data about a patient

NHS Lanarkshire
NHS Lanarkshire Clinical Laboratories
 Biochemistry, Monklands - 01236712113
CPA
 Accredited Medical Laboratory
 Reference No. 1394

Patient ID Number 0209615214	Surname HANEY	Forename JAMES	Date of Birth 02/09/1961	Sex Male	Lab Number 133961143
Requesting Clinician Dr. S [REDACTED]	Requesting Location: [REDACTED] Medical Centre	Copy to Address			

Clinical History
STOMACH CRAMP TFT no therapy.

Results relate to blood unless otherwise stated

Sodium	140	mmol/L	(133-146)	Globulin	26	g/L	(21-37)
Potassium	4.8	mmol/L	(3.5-5.3)				
Chloride	103	mmol/L	(95-108)				
Bicarbonate	24	mmol/L	(22-29)				
Urea	3.4	mmol/L	(2.5-7.8)				
Creatinine	90	umol/L	(60-120)				
eGFR	>59	ml/min/1.73m ²	(>59)				
ALT	17	U/L	(5-55)				
ALP	87	U/L	(30-130)				
Bilirubin Total	9	umol/L	(0-21)				
Albumin	44	g/L	(35-50)				
AST	21	U/L	(10-45)				
LDH	226	U/L	(230-500)				
CCT	31	U/L	(0-90)				
Protein Total	70	g/L	(60-80)				
Albumin	44	g/L	(35-50)				

Specimen Collected 09/10/2013 12:13	Specimen Receipt 09/10/2013 17:08	Reported 11/10/2013 11:30	Reprinted	Last Authorised by [REDACTED]	Page 1 of 2
--	--------------------------------------	------------------------------	-----------	----------------------------------	-------------

Scanned Document
 13-May-2026 LIZMC
 Additional: Scanned Document

Filename: igprda202605131430100.pdf
 Extension: .tif
 Pages:

NHS Confidential: Personal data about a patient

LA 001 001 001



NHS Lanarkshire Clinical Laboratories
 Biochemistry, Monklands - 01236712113



Patient ID Number	Surname	Forename	Date of Birth	Sex	Lab Number
0209615214	HANEY	JAMES	02/09/1961	Male	133961143

Requesting Clinician	Requesting Location:	Copy to Address
Dr. S [REDACTED]	[REDACTED] Medical Centre	

Clinical History
 STOMACH CRAMP TFT no therapy.

Results relate to blood unless otherwise stated

Free T4	15.1	pmol/L	(9.0-21.0)
TSH	1.93	mU/L	(0.20-5.00)
CEA	2.7	µg/L	(0.0-5.0)

Within reference interval. Does not exclude malignancy.


Comment: Tumour marker(s) analysed using the Roche Modular E170.

Specimen Collected	Specimen Receipt	Reported	Reprinted	Last Authorised by	Page 2 of 2
09/10/2013 12:13	09/10/2013 17:08	11/10/2013 11:30		Elliott [REDACTED]	

Scanned Document
 13-May-2026 LIZMC
 Additional: Scanned Document


Filename: igprda202605131430080.pdf
 Extension: .tif
 Pages:

NHS Confidential: Personal data about a patient



NHS
Lanarkshire

NHS Lanarkshire Clinical Laboratories
Microbiology, Monklands - 01236712121



CPA
Accredited Medical Laboratory
Reference No: 1208

Patient ID Number	Surname	Forename	Date of Birth	Sex	Lab Number
0209615214	HANEY	JAMES	02/09/1961	Male	130424310
Requesting Clinician	Requesting Location:	Copy to Address			
Dr. S [REDACTED]	[REDACTED] Medical Centre				
Clinical History					

Specimen: Serum **Anatomical Site:**

H. pylori IgG: POSITIVE

H. pylori serology is unsuitable to determine whether the patient has cleared the infection as IgG levels can remain high for many months after treatment. Please send a stool sample for H. pylori faecal antigen testing to determine whether this is a current active infection or residual antibodies from a previous infection.

Specimen Collected	Specimen Receipt	Reported	Reprinted	Last Authorised by	Page 1 of 1
09/10/2013 12:13	09/10/2013 16:15	11/10/2013 17:30		LIMS	

Scanned Document
13-May-2026 LIZMC
Additional: Scanned Document

Filename: igprda202605131430070.pdf
Extension: .tif
Pages:

NHS Confidential: Personal data about a patient

CHI No: 0209615214
HANEY JAMES
32/09/1961 M
2 Community Place
Belshill ML4 2QG
West Lothian
5076851 Dr Division
52001 MC

DEP 01

DEPRESSION

UPDATE PHONE NUMBER

Current symptoms (duration/severity)

3/2 low mood (anxiety)
Care for son

11/2/14

FHX

Relationships

Living conditions Lives with wife & 2 kids

Social support

Employment/Financial Unemployed

Alcohol/Drugs ~ 12a weak

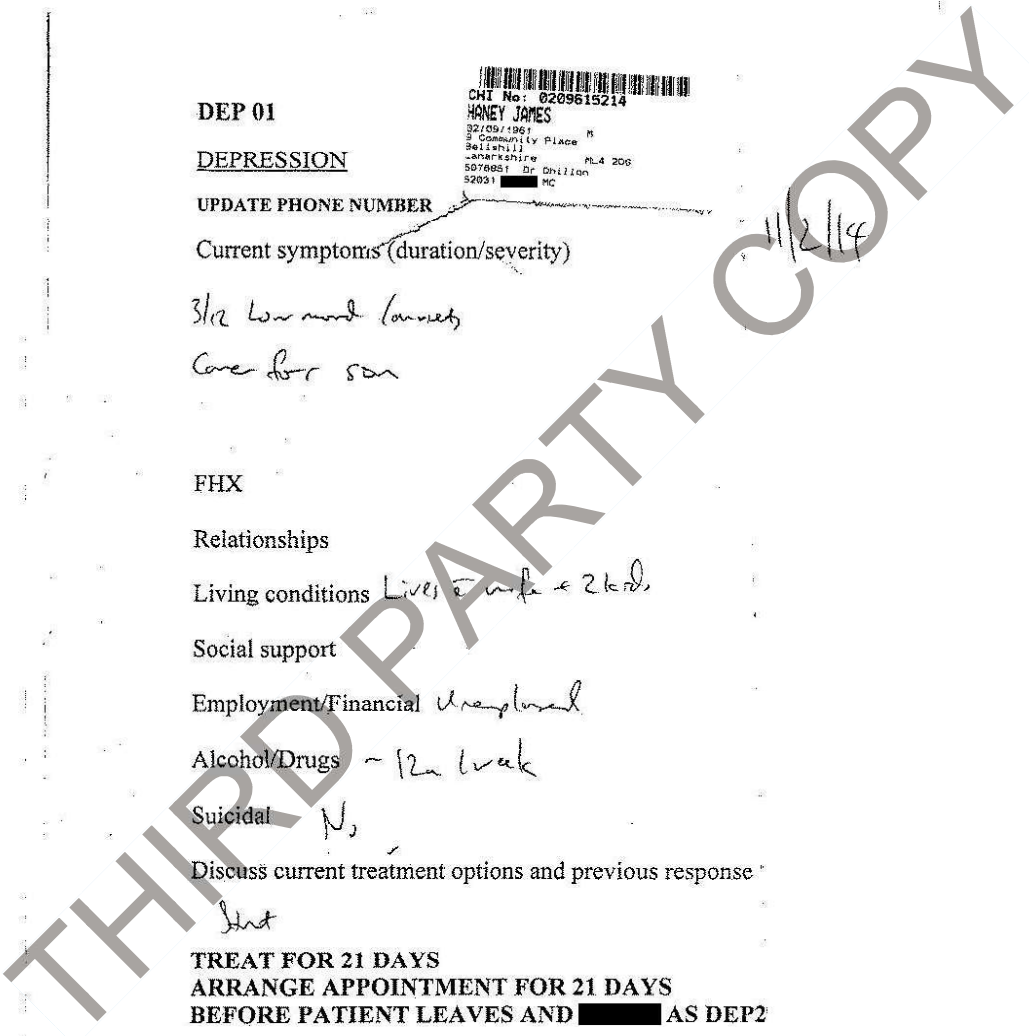
Suicidal No

Discuss current treatment options and previous response

Int

**TREAT FOR 21 DAYS
ARRANGE APPOINTMENT FOR 21 DAYS
BEFORE PATIENT LEAVES AND [REDACTED] AS DEP2**

CODE AT DEP2 APPT



Scanned Document
 13-May-2026 LIZMC
 Additional: Scanned Document

Filename: igprda202605131430050.pdf
 Extension: .tif
 Pages:

NHS Confidential: Personal data about a patient

NHS
 NHS Lanarkshire

COLONOSCOPY REPORT

Name:	James HANEY, 02/09/1961 (M)	Address:	9 Community Place Bellshill Lanarkshire ML4 2DG
CHI No:	0209615214		
Case note no.:	0209615214		
GP:	Dr SS [REDACTED] [REDACTED] Medical Centre 2 Pollock Street Mosscend Bellshill ML4 1QD	Priority:	Open access
		Hospital:	Wishaw Gen Hospital (none)
		Ward:	
		Referring Cons:	Mr M. Downey (Wishaw Surgeons)
		Procedure date:	8th April 2014

Indications

Altered [REDACTED] habit and abdominal pain.
 Clinically important comments: Perianal itch/prone to constipation.

Report

A digital rectal examination was performed.
 The colonoscope was inserted via the anus to the caecum, which was identified positively by the ileocecal valve, the appendicular orifice and the tri-radiate caecal fold. The scope was retroflexed in the rectum.
 The rest of the examination to the limit of insertion was normal.

Diagnosis

Haemorrhoids.

Advice/comments

2 internal haemorrhoids banded. Normal large colon thereafter. Fibre/fluid/nurse-led rectal bleeding clinic number given.

Rosemary [REDACTED]
 Nurse, Endoscopist
 c.c. Mr M. Downey (Wishaw Surgeons)

Consultant/Endoscopist

List consultant: Mr [REDACTED] G Downey
 Endoscopist No1: Rosemary [REDACTED]
 Nurses: M [REDACTED]
 SN C Sneddon

Instrument

WG - CF240DL - 2810452

Premedication

Midazolam (IV) 4 mg
 Pethidine (IV) 50 mg

Bowel Preparation

Movieprep2
 Boston Bowel Prep Total Score 6

TELL NORMAL	<input type="checkbox"/>
SCRIPT	<input type="checkbox"/>
SPEAK TO ORNURSE	<input type="checkbox"/>
ATTEND	<input type="checkbox"/>
FILE	<input checked="" type="checkbox"/>

Scanned Document
 13-May-2026 LIZMC
 Additional:Scanned Document

Filename: igprda202605131430030.pdf
 Extension:.tif
 Pages:

NHS Confidential: Personal data [redacted] patient

to: 02/10/2014 Time: 11:04 To: [redacted] G2031-1 BELLSHILL @ .01698740363
 Page: 001

NHS 24 FAX REPORT

NHS 24 ID:	Call ID: 15162239	Site:	Ayrshire (& Arran)
CHI #:	0209615214	Caller Name:	
Surname:	HANEY	Date/Time Call Received:	02/10/2014 10:53
Forename:	JAMES	Date [redacted] Completed:	
DOB:	02/09/1961	Time [redacted] Completed:	
Gender:	Male	Call Reason:	C50 WORSENING RIB PAIN 3 DAYS SEE AV
Address:	9 Community Place Bellshill Lanarkshire/ML4 2DG	Current Location:	9 Community Place Bellshill Lanarkshire/ML4 2DG
PH NO:	01698295507 (Home)	Special Directions:	Front Door
		Current PH NO:	01698295507 (Home)
Care Provider:	FINDLAY, [redacted]	Care Provider Details:	2 POLLOCK ST MOSSEND BELLSHILL ML4 1DD Scotland

Temporary Resident: No

Referred To: Recommended Action:

CLINICAL SUMMARY
 RIB INJURY FOR 3 DAYS AND HAD A FALL. PAINFUL TO TOUCH. BREATHING IS REALLY PAINFUL. WHEN LYING DOWN REALLY PAINFUL. FEELS GASPING AT TIMES. TOOK COCODAMOL BUT HAS NOT TOOK ANY TODAY. ADVISED TO TAKE SOME TO HELP EASE DISCOMFORT. OUTCOME: A&E ASAP. WISHAW GENERAL HOSPITAL.

PAST MEDICAL HISTORY
MEDICAL PROBLEMS
 CA GROWTH REMOVED FROM NOSE - 2010, DEPRESSION
MEDICATIONS
 AS PER ECS
ALLERGIES
 NONE

Referred Clinical Notes:

T:
 P:
 R:
 BP: /

Print Name:

Signature:

Scanned Document
13-May-2026 LIZMC
Additional:Scanned Document

Filename: igprda202605131430020.pdf
Extension:.tif
Pages:

NHS Confidential: Personal data about a patient

Emergency Discharge Summary Wishaw General Hospital

Doctor SS [REDACTED]
[REDACTED] Medical Centre, 2 Pollock Street, Mossend, Bellshill
ML4 1QD



RE: HANEY, James, 9 Community Place , Bellshill ML4 2DG

CHI: 0209615214

Dear Doctor SS [REDACTED]

Your patient attended Wishaw General Hospital on 02/10/2014 at 11.43
Presenting complaint: fall- left side truncal injury - breathing probs.

Diagnosis:
Diagnosis Notes:
Discharge Type:
Investigations: Nil
Radiology Exams: Nil
Procedures: Nil
Medications: Nil
Follow up: Nil
Notes: Nil

Additional information: Truncal injury 10 days. Called NHS 24 today as pain worse 48hrs. Nil Analgesia taken today. No swelling bruising found, discharged home with Co-Codamol and Ibuprofen

Yours faithfully

TELL NORMAL	<input type="checkbox"/>
SCRIPT	<input type="checkbox"/>
SPEAK TO DR/NURSE	<input type="checkbox"/>
ATTEND	<input type="checkbox"/>
FILE	<input checked="" type="checkbox"/>

THIRD PARTY COPY

Scanned Document
13-May-2026 LIZMC
Additional:Scanned Document

Filename: igprda202605131430000.pdf
Extension:.tif
Pages:

NHS Confidential: Personal data about a patient

Emergency Discharge Summary Monklands District General Hospital



Emergency Department
Monklands District General Hospital
Monkscourt Avenue
ML6 0JS
Telephone : 01236712186

Doctor SS Dhillon
[Redacted] Medical Centre, 2 Pollock Street, Mossend, Bellshill
ML4 1QD

RE: HANEY, James, 9 Community Place, , Bellshill ML4 2DG

CHI: 0209615214

Dear Doctor SS [Redacted],

Your patient attended Monklands District General Hospital on 19/04/2015 at 23:19

Presenting complaint: chest pain

Diagnosis: Delirium, not induced by alcohol and other psychoactive substances - Delirium, unspecified

Diagnosis Notes:

Discharge Type: Admitted

Investigations: Nil

Radiology Exams: Nil

Procedures: Nil

Medications: Nil

Follow up: Nil

Notes: Nil

Additional Information: Acute confusion, ?related to alcohol. Also c/o chest pain. Admitted medicine for MI screen and further assessment of confusion.

Yours faithfully

Dr [Redacted] M [Redacted]

TELL NORMAL	<input type="checkbox"/>
SCRIPT	<input type="checkbox"/>
SPEAK TO DR/NURSE	<input type="checkbox"/>
ATTEND	<input type="checkbox"/>
FILE	<input checked="" type="checkbox"/>

Scanned Document
13-May-2026 LIZMC
Additional:Scanned Document

NHS Confidential: Personal data about a patient



MONKLANDS HOSPITAL
 Lanarkshire Acute Hospitals NHS Trust

Monks court Avenue
 Airdrie ML6 0JS
 Telephone: 01236-748748
 Facsimile: 01236-760015

FINAL DISCHARGE LETTER: No further correspondence is planned

Department of Medicine

GP details
 Dr Dr Campbell |
 Medical Centre
 2 Pollock Street
 Mossend
 Bellshill ML4 1QD

Ward: Ward ERU
 Consultant: Dr S Dundass
 Admission date: 20 January 2015
 Discharge date: 20 January 2015
 Typed date: 24 January 2015
 Page: 1 of 2
 CHI Number: 0209615214

Patient details
 James Haney
 9 Community Place
 Bellshill
 ML4 2DG
 Hospital No: 0209615214

Admitted 20 January 2015 (emergency admission)

Discharged 20 January 2015 (home)

Reasons for admission
 acute confusion
 chest pain

DISCHARGE DIAGNOSIS

Alcohol Excess
 transient amnesia secondary to stress

ICD10Code	Confirmed?	DiagType
Uncoded	<input type="checkbox"/>	
Uncoded	<input type="checkbox"/>	

Major investigations carried out
 ECG
 CXR

Results

There are no investigations pending.

No operations or procedures were carried out.

No follow up arrangements have been made.

No services have been arranged.

TELL NORMAL	<input type="checkbox"/>
SCRIPT	<input type="checkbox"/>
SPEAK TO DR/NURSE	<input type="checkbox"/>
ATTEND	<input type="checkbox"/>
FILE	<input checked="" type="checkbox"/>

THIRD PARTY COPY

NHS Confidential: Personal data about a patient



MONKLANDS HOSPITAL
Lanarkshire Acute Hospitals NHS Trust

Monkscourt Avenue
Airdrie ML6 0JS
Telephone: 01236-748748
Facsimile: 01236-760015

FINAL DISCHARGE LETTER: No further correspondence is planned

Department of Medicine

GP details
Dr Dr Campbell
Medical Centre
2 Pollock Street
Mossend
Bellshill ML4 1QD

Ward: Ward ERU
Consultant: Dr S Dundass
Admission date: 20 January 2015
Discharge date: 20 January 2015
Typed date: 24 January 2015
Page: 2 of 2
CHI Number: 0209615214

Patient details
James Haney
9 Community Place
Bellshill
ML4 2DG
Hospital No: 0209615214

Drug allergy ? NKDA

Additional information

Admitted with acute confusion and episodic chest pain after drinking with friends.
Ethanol level 207 on admission.
ECG normal.
Reviewed by Consultant who felt he was medically fit for discharge.
He has a lot of stress at home looking after [redacted] with bipolar, could GP offer any support for this.

THIRD PARTY COPY

TELL NORMAL	<input type="checkbox"/>
SCRIPT	<input type="checkbox"/>
SPEAK TO DR/NURSE	<input type="checkbox"/>
ATTEND	<input type="checkbox"/>
FILE	<input type="checkbox"/>

Pages [redacted] and approved by: L. DASS Signed: [Signature] Date: 24/1/15

i30 System : ipintermediateLetter V1.1 : 10/02/2009

(BLOCK CAPITALS PLEASE)

Letter copies Copy 1 to Pharmacy Copy 2 to Casenotes Copy 3 to Patient to give to GP Page 2 of 2

Scanned Document
13-May-2026 LIZMC
Additional: Scanned Document

Filename: igprda202605131429550.pdf
Extension: .tif
Pages:

NHS Confidential: [redacted] (date about a patient)

www.nhslanarkshire.org.uk
Department of Dermatology
Secretary 01236 712349

Dr S Findlay
[redacted] Medical Centre
2 Pollock Street
Mossend
Bellshill
ML4 1QD

Monklands Hospital
Monkscourt Avenue
Airdrie
ML6 0JS



Date Dictated: 10/11/2015
Date Typed: 27/11/2015
Ref: 1007347
Letter Ref: [redacted]
Clinic Date: 10/11/2015
CTI Barcode:



Consultant: Dr [redacted] Muller

Dear Dr Findlay

Patient Name: James Haney
Patient date of birth: 02/09/1961
Patient Address: 9 Community Place, Bellshill, ML4 2DG

Diagnosis: Seborrhoeic keratosis.

Thank you very much for referring this 54 year old to the dermatology clinic. He had a BCC excised from his left ala nose area by plastics in 2010. He now presents with a lesion which is in no relation to his previous surgical scar.

On examination he had a rough light brown papule in keeping with a seborrhoeic keratosis. Since he complains of the seborrhoeic keratosis being quite uncomfortable we have treated this with liquid nitrogen today. I have referred him back to your care.

Yours sincerely

Dr F Muller
Locum Consultant Dermatologist

Authorised on 30/11/2015 14:49:31 by Dr [redacted] Muller.

THIRD PARTY COPY

Scanned Document
13-May-2026 LIZMC
Additional: Scanned Document

Filename: igprda202605131429530.pdf
Extension: .tif
Pages:

NHS Confidential: Personal data about a patient



Bowel Screening Centre
Kings Cross
Cleppington Road
Dundee
DD3 8EA



PRIVATE AND CONFIDENTIAL

Dr [REDACTED] FINDLAY
[REDACTED] MEDICAL CENTRE
2 POLLOCK ST
MOSSEND
BELLSHILL
ML4 1QD

Date: 01 Dec 2015
CHI Number: 0209615214

Bowel Screening
Helpline Number: 0800 0121 833

Dear Doctor,

Your patient 0209615214, JAMES HANEY, 9 COMMUNITY PLACE, BELLSHILL, ML4 2DG was invited to participate in the Bowel Screening Programme on 02/09/2015

It is 3 months since your patient was sent a bowel screening invitation and bowel screening test [REDACTED]. As of today's date your patient has not participated. At 6 months your patient will return to recall and be invited again in two years time.

Anything your GP Practice can offer to help your patient's awareness and understanding of the benefits and risks of the Bowel Screening Programme would be appreciated - this will help them to reach an informed decision regarding participation.

If your patient no longer has their screening [REDACTED] it is possible to request another by calling the Scottish Bowel Screening Helpline on 0800 0121 833


Yours sincerely

Professor [REDACTED]
Clinical Director

Scanned Document
 13-May-2026 LIZMC
 Additional:Scanned Document


Filename: igprda202605131429500.pdf
 Extension:.tif
 Pages:

NHS Confidential: Personal data about a patient



NHS
Lanarkshire

NHS Lanarkshire Clinical Laboratories
 Haematology, Wishaw - 01698366393



CPA
Accredited Medical Laboratory
Reference No: 0226

<i>Patient ID Number</i> 0209615214	<i>Surname</i> HANEY	<i>Forename</i> JAMES	<i>Date of Birth</i> 02/09/1961	<i>Sex</i> Male	<i>Lab Number</i> 163717517
<i>Copy to Clinician</i> Dr. S [REDACTED]	<i>Requesting Location:</i> [REDACTED] Medical Centre	<i>Copy to Address</i>			

Clinical History
TATT ITCHY SKIN TFT no therapy.

Results relate to blood unless otherwise stated

Serum B12	331.8	pg/mL	(197.0-771.0)
Serum Folate	6.00	ng/mL	(4.60-18.70)
Serum Ferritin	104.5	ng/mL	(28.0-285.0)

Please note the reference range for Haematinic Assays has changed

<i>Specimen Collected</i> 12/07/2016 11:00	<i>Specimen Receipt</i> 12/07/2016 17:52	<i>Reported</i> 13/07/2016 09:31	<i>Reprinted</i>	<i>Last Authorised by</i> LIMS	<i>Page 2 of 2</i>
---	---	-------------------------------------	------------------	-----------------------------------	--------------------

Scanned Document
 13-May-2026 LIZMC
 Additional: Scanned Document

Filename: igprda202605131429480.pdf
 Extension: .tif
 Pages:

NHS TestMedia: Personal data about a patient



NHS Lanarkshire Clinical Laboratories
 Biochemistry, Wishaw - 01698366391



Patient ID Number	Surname	Forename	Date of Birth	Sex	Lab Number
0209615214	HANEY	JAMES	02/09/1961	Male	163717517

Requesting Clinician	Requesting Location:	Copy to Address
Dr. S [REDACTED]	[REDACTED] Medical Centre	

Clinical History
 TATT ITCHY SKIN TFT no therapy.

Results relate to blood unless otherwise stated

ALT	16	U/L	(5-55)
ALP	106	U/L	(30-130)
Bilirubin Total	10	umol/L	(0-20)
Albumin	44	g/L	(35-50)
AST	18	U/L	(10-45)
LDH	116	U/L	(0-250)
GGT	41	U/L	(0-90)
Glucose	Not performed, see comments		


Laboratory Comment:
 Glucose: Specimen received is unsuitable for test. Fluoride (grey top) specimen required

Specimen Collected	Specimen Received	Reported	Reprinted	Last Authorised by	Page 1 of 2
12/07/2016 11:40	12/07/2016 17:52	14/07/2016 17:30		LIMS	

Scanned Document
 13-May-2026 LIZMC
 Additional: Scanned Document


Filename: igprda202605131429460.pdf
 Extension: .tif
 Pages:

NHS.uk/Media/PersonalData/about-us.html



NHS
Lanarkshire

NHS Lanarkshire Clinical Laboratories
 Biochemistry, Wishaw - 01698366391



CPA
Accredited Medical Laboratory
Reference No: 0200

<small>Patient ID Number</small> 0209615214	<small>Surname</small> HANEY	<small>Forename</small> JAMES	<small>Date of Birth</small> 02/09/1961	<small>Sex</small> Male	<small>Lab Number</small> 163717517
<small>Requesting Clinician</small> Dr. S [REDACTED]	<small>Requesting Location</small> [REDACTED] Medical Centre	<small>Copy to Address</small>			

Clinical History
TATT ITCHY SKIN TFT no therapy.

Results relate to blood unless otherwise stated

Free T4	14.6	pmol/L	(9.0-21.0)
TSH	1.80	mU/L	(0.20-5.00)

<small>Specimen Collected</small> 12/07/2016 11:16	<small>Specimen Receipt</small> 12/07/2016 17:52	<small>Reported</small> 14/07/2016 17:30	<small>Reprinted</small>	<small>Last Authorised by</small> LIMS	<small>Page 2 of 2</small>
---	---	---	--------------------------	---	----------------------------

Scanned Document
13-May-2026 LIZMC
Additional: Scanned Document

Filename: igprda202605131429450.pdf
Extension: .tif
Pages:

Page 1 of 1

NHS Lanarkshire Primary Care Operating Division OOH Call Incident Report

Call number:	88957	Receive Date:	6-Nov-201613:00
Patient's Name:	James Haney	Gender:	M
Date of birth:	2-Sep-1961 (55 years)	Current Address:	9 Community Place Bellshill ML4 2DG
Address:	9 Community Place Bellshill ML4 2DG		
Return Contact No:			
Tel No:	01698 295507		01698 295507
Mobile No:		Call Origin:	NHS24
Priority:	Within 4 Hours	Calltype:	PCC
Received:	6-Nov-201613:00	Arrived PCC:	6-Nov-201616:21
Advised:	13:11	Cons End:	6-Nov-201617:13
Cons start:	6-Nov-201617:01		
Consulting Doctor:	Harbal Bijral	Own doctor:	Findlay

Reported Condition:
VOMITING 18HRS SEE A/V

Consultation details:

History - States he vomited yesterday after eating, and also vomiting today with epigastric discomfort.
No diarrhoea.
See has Omeprazole on Rpt. but states he has not taken it for some time.

Examination - Well, alert, undistressed.
Mild epigastric tenderness.

Diagnosis - Gastritis ?viral GE

Treatment - Adv. fluids (small/freq), adv. re-start PPI, review with own GP pra.

Examination Details ASSESSMENT
Oxygen saturation % 100.0
Systolic BP mmHg 133
Pulse bpm 74
Temperature C 36.5
Diastolic BP mmHg 77

TESTS

Blood glucose level mmol/l 6.0

Followups:

Patient To Contact Surgery

Clinical Codes:

R090, [D]Abdominal pain J17.. Other stomach/duodenal disord.

NHSD details:

Triage NHSD - This call will be transferred directly to a nurse via serious and urgent telephony route.
Advise the caller that if they get cut off you will call them back immediately.

NHSD Comments - VOMITING OVERNIGHT. THINKS SOMETHING IS POSSIBLY LODGED IN WINDPIPE. CHEST PAIN. UNWELL LAST FEW WEEKS, CONSTANTLY TIRES, SLEEPING PROBLEMS. ((User) (Glasgow))


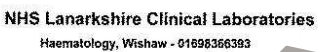

Disposition - Contact GP Practice within 4 Hours (as soon as possible)

file:///M:/PCT1/DOCMAN7/DATA_S1/EDT/INBOX/3527821.HTM

06/11/2016

Scanned Document
 13-May-2026 LIZMC
 Additional: Scanned Document

Filename: igprda202605131429430.pdf
 Extension: .tif
 Pages:

Haematology, Wishaw - 01898366383

Patient ID Number 0209615214	Surname HANEY	Forename JAMES	Date of Birth 02/09/1961	Sex Male	Lab Number 173142293
Requesting Clinician Dr. S ARBUCKLE	Requesting Location: [REDACTED] Medical Centre	Copy to Address			
Clinical History GP REQ					

Results relate to blood unless otherwise stated

Hb	14.9	g/dL	(13.5-18.0)	WBC	5.1	$\times 10^9/L$	(4.0-11.0)
PLT	279	$\times 10^9/L$	(140-450)	Neutrophils	3.3	$\times 10^9/L$	(2.0-7.5)
MCV	94.9	fL	(80.0-100.0)	Lymphocytes	1.2	$\times 10^9/L$	(1.0-4.0)
RBC	4.87	$\times 10^{12}/L$	(4.50-6.50)	Monocytes	0.4	$\times 10^9/L$	(0.2-0.8)
HCT	0.462	L/L	(0.400-0.540)	Eosinophils	0.2	$\times 10^9/L$	(0.0-0.4)
[REDACTED]	30.6	pg	(27.0-32.0)	Basophils	0.1	$\times 10^9/L$	(0.0-0.1)
MCHC	32.3	g/dL	(32.0-36.0)				
RDW	14.4	%	(11.0-16.0)	NRBC's	0.00	$\times 10^9/L$	

Specimen Collected 07/02/2017 11:10	Specimen Receipt 07/02/2017 17:59	Reported 08/02/2017 09:34	Reprinted	Last Authorised by LIMS	Page 1 of 1
---	---	-------------------------------------	------------------	-----------------------------------	--------------------

Scanned Document
 13-May-2026 LIZMC
 Additional:Scanned Document

Filename: igprda202605131429410.pdf
 Extension:.tif
 Pages:

NHS Confidential: Personal data about a patient



NHS Lanarkshire Clinical Laboratories
 Biochemistry, Wishaw - 01698366391



Patient ID Number 0209615214	Surname HANEY	Forename JAMES	Date of Birth 02/09/1961	Sex Male	Lab Number 173142293
Copy to Clinician Dr. S ARBUCKLE		Requesting Location: [REDACTED] Medical Centre		Copy to Address	
Clinical History GP REQ					

Results relate to blood unless otherwise stated

Sodium	143	mmol/L	(133-146)	HDL Cholesterol	1.10	mmol/L	(0.90-1.80)
Potassium	5.0	mmol/L	(3.5-5.3)	LDL Chol. (Calc)	2.8	mmol/L	(0.0-3.0)
Chloride	103	mmol/L	(95-108)	Chol./HDL Ratio	4.4		(0.0-5.0)
Bicarbonate	29	mmol/L	(22-29)				
Urea	3.0	mmol/L	(2.5-7.8)				
Creatinine	97	umol/L	(60-120)				
EGFR	>59	ml/min/1.73m ²	(>59)				
ALT	16	U/L	(5-55)				
ALP	103	U/L	(30-130)				
Bilirubin Total	16	umol/L	(0-20)				
Albumin	42	g/L	(35-50)				
AST	20	U/L	(10-45)				
LDH	148	U/L	(0-250)				
CCP	41	U/L	(0-90)				
Cholesterol	4.8	mmol/L	(0.0-5.0)				
Triglyceride	1.90	mmol/L	(0.00-2.30)				

Specimen Collected 07/02/2017 11:10	Specimen Receipt 07/02/2017 17:59	Reported 08/02/2017 11:31	Reprinted	Last Authorised by LHMS	Page 1 of 1
---	---	-------------------------------------	------------------	-----------------------------------	--------------------

Scanned Document
13-May-2026 LIZMC
Additional: Scanned Document

Filename: igprda202605131429390.pdf
Extension: .tif
Pages:

NHS Confidential: [redacted] (note about a patient)

www.nhslanarkshire.org.uk
Department of General Surgery
01698 366793
Surgical

James Haney
9 Community Place
Bellshill
ML4 2DG

Wishaw General Hospital
50 Netherton Street
Wishaw
ML2 0DP



Date Dictated: 05/04/2017
Date Typed: 06/04/2017
Ref: 1623872
Letter Ref: JC
CHI Barcode: *0209615214*

Consultant: Mr Olusegun Komolafe

Dear [redacted]

Patient Name: James Haney
Patient date of birth: 02/09/1961
Patient Address: 9 Community Place, Bellshill, ML4 2DG

This is a note about the Endoscopy and Colonoscopy that Dr [redacted] performed for you recently. I am glad to see that nothing worrisome was seen. She suspected that you had a bit of thrush in your gullet and the biopsies she has taken from your gullet have confirmed this. Your large bowel was unremarkable which is reassuring. I suspect that you probably do have an element of Irritable Bowel Syndrome. If you look at the website www.patient.co.uk there is a very useful IBS Condition Leaflet and an IBS Diet Sheet that you can print off and follow the instructions, to manage the condition yourself. Nothing more requires to be done and I am happy to leave your further care with your GP.

Kindest regards,
Mr Segun Komolafe
Consultant Surgeon
Hon. Clinical Senior Lecturer

Authorised on 13/04/2017 20:27:35 by Segun Komolafe.

(D) Dr S Findlay
[redacted] Medical Centre
2 Pollock Street
Mossend
Bellshill
ML4 1QD

NHS CONFIDENTIAL Personal data should be protected



NHS Lanarkshire

COLONOSCOPY REPORT

Name:	James HANEY, 02/09/1961 (M)	Address:	9 Community Place Bellshill Lanarkshire ML4 2DG
CHI No:	0209615214		
Case note no.:	0209615214		
GP:	Dr S Findlay [redacted] Medical Centre 2 Pollock Street Mossend Bellshill ML4 1QD	Priority:	Urgent
		Hospital:	Wishaw Gen Hospital (none)
		Referring Cons:	Mr Segun Komolafe (Wishaw Surgeons)
		Procedure date:	17th March 2017

Indications
 Acute constipation.

Report
 A digital rectal examination was performed. The colonoscope was inserted via the anus to the caecum, insertion confirmed by caecal photograph. The caecum was identified positively by the ileocaecal valve, the appendicular orifice and the tri-radiate caecal fold. The scope was retroflexed in the rectum. The examination to the limit of insertion was normal.

Medication
 Continue medication.

Advice/comments
 Suspect this is IBS - left sided abdo pain in conjunction with a change in bowel habit to constipation - going once or twice a week. Senna has helped. Weight loss is not really an issue. Colon normal - bowel prep had worked reasonably but there were still pools of liquid stool and prep that had to be sucked out. Very anxious.

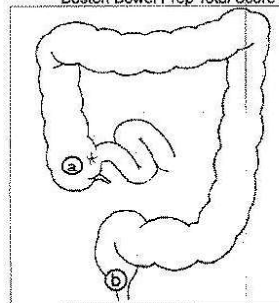
Miss [redacted]
 Staff Grade Surgeon

Consultant/Endoscopist
 Miss [redacted]

Instrument
 WG - Q260DL - 2211668

Premedication
 Midazolam (IV) 3 mg
 Pethidine (IV) 50 mg

Bowel Preparation
 Moviprep
 Boston Bowel Prep Total Score 9



a: Caecum (photographed)
 b: Rectum (photographed)

TELL NURSE	<input checked="" type="checkbox"/>
SCRIPT	<input type="checkbox"/>
SPEAK TO DR/NURSE	<input type="checkbox"/>
ATTEND	<input checked="" type="checkbox"/>
FILE	<input type="checkbox"/>

NHS Confidential: Personal data about a patient



GASTROSCOPY REPORT

Name:	James HANEY, 02/09/1961 (M)	Address:	9 Community Place Bellshill Lanarkshire ML4 2DG
CHI No:	0209615214		
Case note no.:	0209615214		
GP:	Dr S Findlay [redacted] Medical Centre 2 Pollock Street Mossend Bellshill ML4 1QD	Priority:	Repeat/Scheduled
		Hospital:	Wishaw Gen Hospital (none)
		Ward:	
		Referring Cons:	Mr Segun Komolafe (Wishaw Surgeons)
		Procedure date:	17th March 2017

Indications
 Weight loss.

Report
 The procedure was completed successfully to D2.

Diagnosis
 OESOPHAGUS. ? candida.
 STOMACH. Gastritis.
 DUODENUM. Normal.

Medication
 Continue medication.

Follow up
 Awaiting pathology results.

Advice/comments
 I think this is antral biliary gastritis - not erosive but a clo done as there was mild inflammatory change in D1 as well.

~There is a patch in the mid oesophagus of what looks like candid but Id wait for the biospy first - it doesnt look suspicious - it looks like candida but he hasnt been on steroids or antibiotics and doesnt use inhalors to explain it.

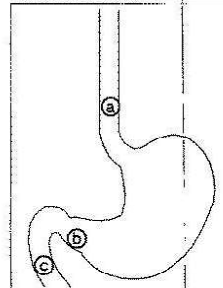
Miss [redacted]
 Staff Grade Surgeon

TELL NORMAL
 SCRIPT
 SPEAK TO DR/NURSE
 ATTEND
 FILE

Consultant/Endoscopist
 Miss [redacted]

Instruments
 WG - GIFH260 - 2345408
 Disposable forceps

Premedication
 Midazolam (IV) 2.5 mg
 Xylocaine (Spray) 100 mg



a: Lower oesophagus (photographed)
 b: Prepyloric region (photographed)
 c: Second part (photographed)

Specimens taken
 Biopsy (x2 site a)
 Urease test for H.pylori (b)

clo required

NHS Confidential - For use only about a patient



COLONOSCOPY REPORT

Name:	James HANEY, 02/09/1961 (M)	Address:	9 Community Place Bellshill Lanarkshire ML4 2DG
CHI No:	0209615214		
Case note no.:	0209615214		
GP:	Dr S Findlay [Redacted] Medical Centre 2 Pollock Street Mossend Bellshill ML4 1QD	Priority:	Urgent
		Hospital:	Wishaw Gen Hospital (none)
		Ward:	
		Referring Cons:	Mr Segun Komolafe (Wishaw Surgeons)
		Procedure date:	17th March 2017

Indications
Acute constipation.

Report
A digital rectal examination was performed. The colonoscope was inserted via the anus to the caecum, insertion confirmed by caecal photograph. The caecum was identified positively by the ileocecal valve, the appendicular orifice and the tri-radiate caecal fold. The scope was retroflexed in the rectum. The examination to the limit of insertion was normal.

Medication
Continue medication.

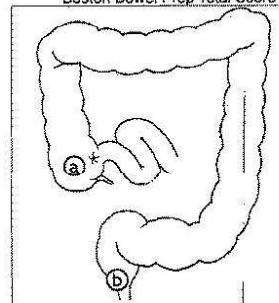
Advice/comments
Suspect this is IBS - left sided abdo pain in conjunction with a change in bowel habit to constipation - going once or twice a week. Senna has helped. Weight loss is not really an issue. Colon normal - bowel prep had worked reasonably but there were still pools of liquid stool and prep that had to be sucked out. Very anxious.

Miss [Redacted]
Staff Grade Surgeon

Consultant/Endoscopist
Miss [Redacted]
Instrument
WG - Q260DL - 2211668

Premedication
Midazolam (IV) 3 mg
Pethidine (IV) 50 mg

Bowel Preparation
Moviprep
Boston Bowel Prep Total Score 9



a. Caecum (photographed)
b. Rectum (photographed)

TELL NORMAL
SCRIPT
SPEAK TO DR/NURSE
ATTEND
FILE

THIRD PARTY COPY