

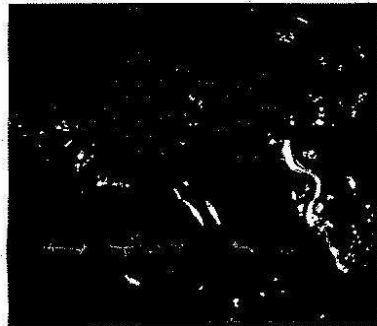NHS Confidential: Personal data about a patient

NHS Lanarkshire

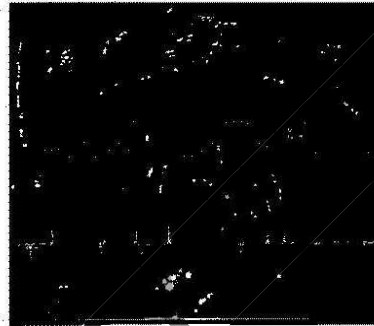
Name:	James HANEY	Address:	9 Community Place
CHI No:	0209615214		Bellshill
			Lanarkshire
Date of birth:	02/09/1961	ML4 2DG	
Case note No:	0209615214		

Page 1 of 1

Procedure date: 17th March 2017



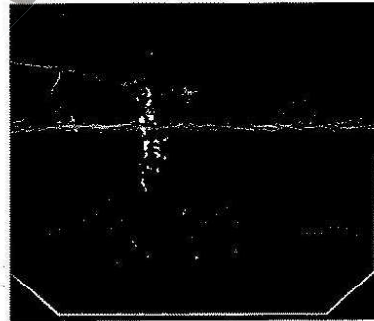
Site a: Caecum



Site a: Caecum



Site a: Caecum



Site b: Rectum

Scanned Document
13-May-2026 LIZMC
Additional: Scanned Document

Filename: igprda202605131429300.pdf
Extension: .tif
Pages:

NHS Confidential - Personal data about a patient



GASTROSCOPY REPORT

Name: James HANEY, 02/09/1961 (M) Address: 9 Community Place
 CHI No: 0209615214 Bellshill
 Case note no.: 0209615214 Lanarkshire
 ML4 2DG

GP: Dr S Findlay Priority: Repeat/Scheduled
 [Redacted] Medical Centre Hospital: Wishaw Gen Hospital
 2 Pollock Street Ward: (none)
 Mossend Referring Cons: Mr Segun Komolafe (Wishaw Surgeons)
 Bellshill Procedure date: 17th March 2017
 ML4 1QD

Indications
 Weight loss.

Report
 The procedure was completed successfully to D2.

Diagnosis
 OESOPHAGUS. ? candida. *code already coded*
 STOMACH. Gastritis
 DUODENUM. Normal.

Medication
 Continue medication.

Follow up
 Awaiting pathology results.

Advice/comments
 I think this is antral biliary gastritis - not erosive but a clo done as there was mild inflammatory change in D1 as well.

-There is a patch in the mid oesophagus of what looks like candid but Id wait for the biospy first - it doesnt look suspicious - it looks like candida but he hasnt been on steroids or antibiotics and doesnt use inhalors to explain it.

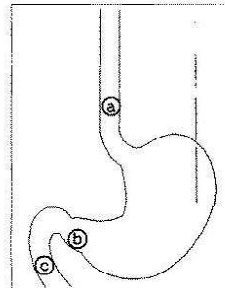
Miss [Redacted]
 Staff Grade Surgeon

Consultant/Endoscopist
 Miss [Redacted]

Instruments
 WG - GIFH280 - 2345408
 Disposable forceps

Premedication
 Midazolam (IV) 2.5 mg
 Xylocaine (Spray) 100 mg

TELL NORMAL	<input type="checkbox"/>
SCRIPT	<input type="checkbox"/>
SPEAK TO DN/NURSE	<input type="checkbox"/>
ATTEND	<input type="checkbox"/>
FILE	<input type="checkbox"/>



a: Lower oesophagus (photographed)
 b: Prepyloric region (photographed)
 c: Second part (photographed)

Specimens taken
 Biopsy (x2 site a)
 Urease test for H.pylori (b)

clot + negative

THIRD PARTY COPY


NHS Confidential. For use only about a patient

NHS Lanarkshire

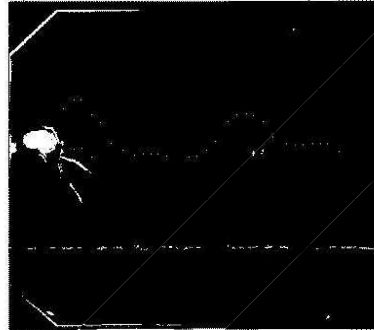Name: James HANEY Address: 9 Community Place
CHI No: 0209615214 Bellshill
Lanarkshire
Date of birth: 02/09/1961
Case note No: 0209615214 ML4 2DG

Page 1 of 1

Procedure date: 17th March 2017



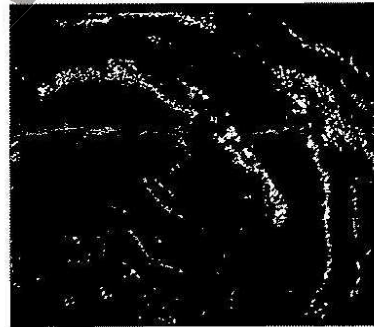
Site a: Lower oesophagus



Site a: Lower oesophagus



Site b: Prepyloric region



Site c: Second part

Scanned Document
13-May-2026 LIZMC
Additional: Scanned Document

Filename: igprda202605131429260.pdf
Extension: .tif
Pages:

NHS Lanarkshire Primary Care Operating Division OOH Call Incident Report

Call number:	24365	Receive Date:	11-May-2019 14:22
Patient's Name:	James Haney		
Date of birth:	2-Sep-1961 (57 years)	Gender:	M
Address:	9 Community Place Bellshill	Current Address:	9 Community Place Bellshill
	ML4 2DG		ML4 2DG
Return Contact No:			
Tel No:	07880 235234		07880 235234
Mobile No:			
Priority:	Within 4 Hours	Call Origin:	NHS24
Received:	11-May-2019 14:22	Calltype:	PCC
Advised:	14:39	Arrived PCC:	11-May-2019 19:38
Cons start:	11-May-2019 20:55	Cons End:	11-May-2019 20:58
Consulting Doctor:	██████████	Own doctor:	██████████ Findlay

Reported Condition:
PAIN IN GROIN AREA FOR 3 WEEKS

Consultation details:

History - Constipated on and off for years. Had a colonoscopy last year which was normal. Takes fybogel intermittently when constipated. Goes for a few days with no bowel motion and then 2-3 large stools in a day. Has had a small hard bowel motion 2 hours ago.
Called NHS 24 as for last 2 days has been very constipated with throbbing rectal pain and now has an inflamed red rash around his anus. Tried a glycerol supp yesterday with no effect. Also has LIF pain which has eased since opening bowels earlier this evening. No PR bleeding. No nausea or vomiting.
Discussed diet - poor, low fibre, no fruit/veg etc and predominantly drinks fizzy drinks
No other medical problems

Examination - news=0
Looks well. Note normal obs
Abdo soft, non tender, no masses
PR with consent - candidal inflamed rash round perianal skin with satellite lesions. PR unable to be performed due to pain ++ on insertion of finger. No fissures seen.

Diagnosis - Fungal infection plus constipation

Treatment - Canestan HC BD
REstart fybogel and advised to take regularly
Better diet discussed
Will see own GP if rash worsening or not resolving

1998 Constitution, Practice, and Procedure

Examination **ASSESSMENT**
Details - **Oxygen saturation % 100.0**
Systolic BP mmHg 130
Pulse bpm 65
Temperature C 36.4
Diastolic BP mmHg 78

LUNGS
Rate of respiration 13

Prescriptions:
Canesten HC cream (Bayer Plc) 1 application - TWICE a DAY - topical 30.00
Fybogel 3.5g effervescent granules sachets plain SF (Reckitt Benckiser Healthcare (UK) Ltd) 1 sachet - TWICE a DAY - oral 30.00

Followups:
Return To Gp Only if Condition Not Resolved (V)

Clinical Codes:
I9C2. Constipated

NHSD details:
Disposition **Contact GP Practice within 4 Hours (ASAP)**

Scanned Document
13-May-2026 LIZMC
Additional:Scanned Document

Filename: igprda202605131429220.pdf
Extension:.tif
Pages:

NHS Computer System (not a patient)

NHS Lanarkshire Primary Care Operating Division OOH Call Incident Report

Call number:	18088	Receive Date:	2-Aug-2020 19:19
Patient's Name:	James Haney		
Date of birth:	2-Sep-1961 (58 years)	Gender:	M
Address:	9 Community Place Bellshill	Current Address:	9 Community Place Bellshill
	ML4 2DG		ML4 2DG
Return Contact No:			
Tel No:	07794 268962		07794 268962
Mobile No:			
Priority:	Within 4 Hours	Call Origin:	NHS24
Received:	2-Aug-2020 19:19	Calltype:	PCC
Advised:	19:31	Arrived PCC:	2-Aug-2020 20:54
Cons start:	2-Aug-2020 21:31	Cons End:	2-Aug-2020 21:49
Consulting Doctor:	GAVIN MACLEOD	Own doctor:	Findlay

Reported Condition:
RECTUM PAIN 3 WEEKS

Consultation details:

History - Long hx of constipation over several years, ahs attended OOH re this before. Last d/w own GP before lockdown. Called tonight as has been having worsening rectal pain and difficulty opening bowels. Is worried he has a blockage in bowels. Has previously been for scopes. Says has been taking laxido up to 5 per day- note hasn't had this prescribed since January. Has supps at home also. Is passing flatus.

Examination - Seems well. Abdo soft and non-tender, BS OK. No masses or peritonism.

Diagnosis - Constipation

Treatment - Reassured no blockage. Discussed why constipation isn't something that can be dealt with properly OOH- should be seeing GP re this and should see GP if persists. Discussed using reg laxido 3 sachets per day until bowels move and reduce dose gradually after. Gave Microlax enema to try tonight.

Examination Details - ASSESSMENT
Oxygen saturation % 99.0
Systolic BP mmHg 140
Pulse bpm 61
Temperature C 36.5
Diastolic BP mmHg 75

LUNGS

NHS Computer System (not a patient)

Rate of respiration 18

Followups:

Return To Gp Only If Condition Not Resolved

Clinical Codes:

19C2. Constipated

NHSD details:

Disposition **Contact GP Practice within 4 Hours (ASAP)**

THIRD PARTY COPY

Scanned Document
13-May-2026 LIZMC
Additional:Scanned Document

Filename: igprda202605131429190.pdf
Extension:.tif
Pages:

NHS Computer System (not a patient)

NHS Lanarkshire Primary Care Operating Division OOH Call Incident Report

Call number:	92412	Receive Date:	25-Jun-202123:48
Patient's Name:	James Haney	Gender:	M
Date of birth:	2-Sep-1961 (59 years)	Address:	9 Community Place Bellshill
Address:	9 Community Place Bellshill	Current Address:	9 Community Place Bellshill
Return Contact No:	ML4 2DG		ML4 2DG
Tel No:	07794 268962		07794 268962
Mobile No:			
Priority:	Within 4 Hours	Call Origin:	NHS24
Received:	25-Jun-202123:48	Calltype:	PCC
Advised:	00:04	Arrived PCC:	26-Jun-202102:54
Cons start:	26-Jun-202103:03	Cons End:	26-Jun-202103:28
Consulting Doctor:	█████ McIntyre	Own doctor:	█████ Findlay

Reported Condition:
STOMACH - 14 HRS

Consultation details:

History - see hx - abdo pain - increasing since early this morning - constipated 4/7
- no vomiting - no urinary symptoms - will need F2F ?? for surgeons
depending on acuity - no covid sx - pccc 4hrs ██████ - suitable for np /
anp

bowels sluggish for a number of years - no blood / mucus - last bm 2/7
ago - patient stated that he perceives day time general practice is
difficult to access

Examination -
u - urine sample clear

abdo soft, tender lower abdo, no guarding, bs ok - pr declined by
patient

Diagnosis - abdo pain / constipation

Treatment - discussed options - looking for treatment - is aware he needs to consult
GP re f/u / ongoing management / investigation - recall advice

Examination Details

ASSESSMENT
- Oxygen saturation % 98.0
- Systolic BP mmHg 117
- Pulse bpm 71
- Temperature C 36.0
- Diastolic BP mmHg 72

NHS Computer System (HIS) v 1.0

ASTHMA ASSESSMENT CARE BUNDLE
Rate of respiration 16

Prescriptions:

Laxido Orange oral powder sachets sugar free (Galen Ltd) 2 caps per day - can increase to 4 sachets / day and ultimately 6 sachets / day in increments if required
20.00 Glycerol 4g suppositories 1 suppository - when required - rectal 12.00

Followups:

Patient To Contact Surgery

Clinical Codes:

R090. [D]Abdominal pain

NHSD details:

Disposition **Contact GP Practice within 4 Hours (ASAP)**

THIRD PARTY COPY

Scanned Document
 13-May-2026 LIZMC
 Additional:Scanned Document

Filename: igprda202605131429150.pdf
 Extension:.tif
 Pages:

NHS Copyright. Personal data should be masked.

NHS Lanarkshire Primary Care Operating Division OOH Call Incident Report

Call number:	91541	Receive Date:	30-Nov-202100:25
Patient's Name:	JamesHaney	Gender:	M
Date of birth:	2-Sep-1961 (60 years)	Current Address:	9 Community Place Bellshill
Address:	9 Community Place Bellshill		
	ML4 2DG		ML4 2DG
Return Contact No:			
Tel No:	07794 268962		07794 268962
Mobile No:			
Priority:	Within 2 Hours	Call Origin:	NHS24
Received:	30-Nov-202100:25	Calltype:	PCC
Advised:	00:54	Arrived PCC:	
Cons start:	30-Nov-202101:05	Cons End:	30-Nov-202101:05
Consulting Doctor:		Own doctor:	Findlay

Reported Condition:
STOMACH PAIN, 3 DAYS

Consultation details:
 Treatment: the patient has been advised the service has no capacity to deal with your call at this time. please either contact your own Gp when they open or attend your nearest A+E dept.

Followups:
Redirection

Clinical Codes:

NHSD details:
 Disposition: Contact GP Practice within 4 Hours (ASAP)

Scanned Document
 13-May-2026 LIZMC
 Additional:Scanned Document

Filename: igprda202605131429130.pdf
 Extension:.tif
 Pages:

NHS Confidential: Personal data about a patient

Emergency Discharge Summary University Hospital Monklands

NHS
Lanarkshire

Emergency Department
 University Hospital Monklands
 Monkscourt Avenue
 ML6 0JS
 Telephone : 01236712186

S Findlay
 [REDACTED] Medical Centre, 2 Pollock Street, Mossend, Bellshill
 ML4 1GD

RE: HANEY, James. 9 Community Place . , Bellshill ML4 2DG

CH: 0209615214

Dear Doctor S Findlay ,

Your patient attended University Hospital Monklands on 31/05/2022 at 02:20

The presenting complaint was: eta- 0300, ed- OOH- retention of urine

Diagnosis: Constipation

Diagnosis Notes:

Investigations:

Radiology Exams:

Procedures:

Medications:

Follow up:

Notes:

Additional Information: C/O abdominal distension and constipation. No obstruction. Discharged with laxido. Mr Haney has been c/o altered bowel habit recently - constipation for a few months then with episodic diarrhoea. Bloods today NAD. Discharged with advice if concerned re altered bowel habits to d/w primary care team re onward referral for further investigation to exclude malignancy. Lactulose 15mls PRN BD prescription issued today

Yours faithfully

[REDACTED] (ian) [REDACTED]

Scanned Document
 13-May-2026 LIZMC
 Additional:Scanned Document

NHS Confidential: Personal data about a patient



NHS Lanarkshire Primary Care Operating

1 Patient Contacts for [REDACTED] MEDICAL CENTRE

Page 1 of 2

NHS Confidential: Personal data about a patient

Patient : James Haney
 (Gender: Male) (DOB: 02/09/1961) (Age: 60 years) (CHI: 0209615214)

Case No 95680

Informational Outcomes

Admitted To Hospital -
 Emergency Care Summary viewed on case

Current Address

9 Community Place Bellshill

Home Address (If Different)

ML4 2DG

Current Phone 07794 268962

Home Phone (If Different)

NHS 24 Advice by Caroline [REDACTED] (Call Taker Si) ()

Triage Start
Triage Start 01:00
Triage End
Triage End 01:18

PCC3 PCEC within 2 Hrs
 Clinical summary created by: [REDACTED] (Call Taker Si) () [31/05/2022 01:18:08]
 Reason for call: BACK & STOMACH PAIN - 2HRSConfirmed Symptom(s):
 Rash associated with symptoms other than photophobia and neck stiffness
 Fever and unwell with rash
 Endpoint Management Selected (CCT)
 Rash and unwell

Symptom(s) not found:
 No fever
 No chest pain front or back
 No cold hands and feet
 No rash like small bruises or pin pricks which are purple or red

Risk Factor(s):
 No travel outside Europe in last 21 days or to an affected country

Call Detail(s):

Clinical supervisor (First Triage): E FAULKNER SCN
 31/05/2022 01:02:22 SMITHC. H/O CONSTIPATED, THINKS IT'S A KIDNEY AREA... SEVERE LOWER
 ABDOMEN & BACK PAIN, TENDER TO TOUCH, DIFFICULTY MOBILISING, RECENT DIARRHOEA NO BO
 SINCE YESTERDAY & STAIRES NOT PU TODAY, DIFFICULTY TRIAGE. PCEC 2 HRS, HUR TO ARRANGE
 PLEASE.

Outcome: PCEC within 2 Hrs

Case Questions

Adastra Consult by McIntyre, [REDACTED]

Consult Start 01:48
Consult End 01:56

History

24 hr hx of retention of urine - now back pain - needs catheter - A&E MDGH asap

Report

Report produced by Adastra Version 3 - 31/05/2022 02:16:55

Statistics:

NHS Confidential: Personal data about a patient

Case No 95680

Patient : James Haney
(Gender: Male) (DOB: 02/09/1961) (Age: 60 years) (CHI: 0209615214)

Informational Outcomes

Admitted To Hospital -
Examination

Diagnosis

Treatment

Prescriptions

THIRD PARTY COPY

Report
Statistics:

Report produced by Adastra Version 3 - 31/05/2022 02:16:55

Scanned Document
13-May-2026 LIZMC
Additional:Scanned Document

Filename: igprda202605131429080.pdf
Extension:.tif
Pages:

NHS Computer Personal Health System

NHS Lanarkshire Primary Care Operating Division OOH Call Incident Report

Call number:	60874	Receive Date:	5-Sep-202423:23
Patient's Name:	James Haney	Gender:	M
Date of birth:	2-Sep-1961 (63 years)	Current Address:	9 Community Place Bellshill ML4 2DG
Address:	9 Community Place Bellshill ML4 2DG		
Return Contact No:			
Tel No:	07794 268962		07794 268962
Mobile No:			
Priority:	within 1 hour	Call Origin:	NHS24
Received:	5-Sep-202423:23	Calltype:	Advice
Advised:	23:56	Arrived PCC:	
Cons start:	6-Sep-202401:47	Cons End:	6-Sep-202401:57
Consulting Doctor:	GAVIN MACLEOD	Own doctor:	Findlay

Reported Condition:
ABDO PAIN 15 HRS

Consultation details:

History - Telephone advice. Has had pain in rectum for several months. Feels pain is worsening. Gets pain in penis as well as scrotum/ testicles. Says he hasn't seen his GP yet as he's been unable to get appt- last tried calling last week. Has developed new L lower abdo pain he feels radiates to back passage, in past 2-3/7. Has had ?colonoscopy in the past and ? polyp removal.

Examination - Sounds well

Diagnosis - Chronic Anorectal pain, worsening
New L sided abdo pain

Treatment - Discussed symptoms and limited options for managing or investigating chronic anorectal pain. Discussed appt, but is happy to contact own GP after 8am- can patient have urgent appt?

Followups:

Patient To Contact Surgery
Telephone Advice

Clinical Codes
1969. Abdominal pain

NHSB details:

Disposition - Contact GP Practice within 4 Hours (ASAP)

THIRD PARTY COPY

Scanned Document
13-May-2026 LIZMC
Additional:Scanned Document

Filename: igprda202605131429040.pdf
Extension:.tif
Pages:

NHS Confidential: Personal data about a patient

Emergency Discharge Summary University Hospital Monklands



S Findlay
[Redacted] Medical Centre, 2 Pollock Street, Mossend, Bellshill
ML4 1GD

RE: HANEY, James. 9 Community Place . . Bellshill ML4 2DG

CH: 0209615214

Dear Doctor S Findlay ,

Your patient attended University Hospital Monklands on 24/10/2024 at 11:02

The presenting complaint was: numbness in face yesterday and this morning - pain in head going down shoulder and arm - slurred speech

Diagnosis: Stroke, Not Specified As Haemorrhage Or Infarction

Diagnosis Notes:

Investigations:

Radiology Exams:

Procedures:

Medications:

Follow up:

Notes:

Additional Information: Admit under medics

Information:

Yours faithfully

[Redacted] Rae

THIRD PARTY COPY

Scanned Document
13-May-2026 LIZMC
Additional:Scanned Document

NHS Computer Personal data and system

Monklands Hospital Monkscourt Avenue Airdrie ML6 0JS	Discharge Letter & Prescription
---	--

page 1 of 2

To: S FINDLAY BRUCE MEDICAL CENTRE	Re: JAMES HANEY 9 COMMUNITY PLACE , BELLSHILL , LANARKSHIRE , ML4 2DG DOB: 02/09/1961 Hosp. No.: CHI No.: 0209615214
--	--

Date of Admission: 24/10/2024 **Ward:** ML Ward 21
Mode of Admission: **Consultant:** Dr [REDACTED] (GERIATRIC MEDICINE-AB)
Admission Reason: Facial Droop and Dysarthria
Discharge Date: 01/11/2024 **Follow Up:**

Diagnoses (R) arm/leg altered sensation ?cause ??glial tumour

Co-Morbidities Gastritis
 Basal Cell Carcinoma 2010

Investigations CT Head - nit acute
 MRI head - Small focus of confluent T2 signal posterior parietal lobe ?differential included glial tumour.
 MRI head with contrast - Appearances remain indeterminate - malignancy could not be fully ruled out.
 CT chest/abdo/pelvis - no evidence of malignancy
 ECG - NAD
 ECHO - NAD

Clinical Progress Mr Haney was admitted with (R) facial droop and abnormal sensation at corner of mouth. He then developed pain in his neck/back/flank and (R) leg. Describes 'icy sensation' to lateral aspect of right arm and leg. Also some leg painfulness.
 He has had numerous radiological investigations.
 Also reviewed by Neurology as an inpatient, it was noted he had some (R) arm twitching at times, James stops quinine for weeks, suggested if persists could try an antiepileptic (250mg OD for a week then up titrate to 250mg BD). No other focal neurology.
 MRI with contrast was reviewed by Neuroradiology and discussed with Neurosurgery, abnormality not definitely identified, low grade neoplasm. The MRI will be discussed at the Neurosurgical MDT and they will liaise with discharging Consultant/Neurology as required.
 At the point of discharge, we do not have a definite diagnosis.

Follow-up Neurosurgical MDT
 Neurological bloods outstanding

Medication Changes No new medications

L/T = Long-term - Please [REDACTED] a minimum 7 day supply of medicines will be dispensed by the hospital pharmacy unless otherwise stated.

Discharged by: ANP Darren Brown

page 1 of 2

NHS Computer Personal Data and a patient

Monklands Hospital Monkscourt Avenue Airdrie ML6 0JS	Discharge Letter & Prescription
---	--

page 2 of 2

To: S FINDLAY BRUCE MEDICAL CENTRE	Re: JAMES HANEY 9 COMMUNITY PLACE , BELLSHILL , LANARKSHIRE , ML4 2DG DOB: 02/09/1961 Hosp. No.: CHI No.: 0209615214
--	--

Allergy/intolerance	Reaction
***No Known Drug Allergies	

Allergy records are as recorded at time and date of printing.

Drug	Dose	Route	Frequency	Duration	GP to continue
No Drugs	0 n/a	n/a	n/a	Patient's Own	N

THIRD PARTY COPY

if IT = 1 long-term - Please note a minimum 7 day supply of medicines will be dispensed by the hospital pharmacy unless otherwise stated.

Discharged by:	ANP	Darren	Brown
-----------------------	-----	--------	-------

page2 of 2

Scanned Document
13-May-2026 LJZMC
 Additional:Scanned Document

Filename: igprda202605131428590.pdf
Extension: .tif
Pages:

NHS Confidential: Personal data about a patient

Deborah Houston
Multi Disciplinary Team Co-ordinator
6th Floor, Institute of Neurological Sciences
Southern General Hospital
1345 Govan Road
Glasgow G81 4TF

0141 232 7500
Deborah.Houston@ggc.scot.nhs.uk

2024-NOV-06

DR PARK
[REDACTED] MEDICAL CENTRE
2 POLLOCK STREET
BELLSHILL
ML4 1D

Dear DR PARK

JAMES HANEY CHI: 0209615214
Neuro-oncology Patient Outcome

The above patient has been discussed at our Neuro-oncology MDT meeting on 2024-NOV-06.

I have provided you with a copy of their outcome for your records and information.

This outcome can be influenced by subsequent review when appropriate communication will be forwarded by the relevant clinician as quickly as possible.

Yours sincerely,

[REDACTED] Houston
MDT Co-ordinator

THIRD PARTY COPY

NHS Confidential: Personal data about a patient

INSTITUTE OF NEUROLOGICAL SCIENCES
Queen University Hospital.
 Patient Referral Form for Neuro-oncology MDT Meeting.

SECTION 1. FROM CONSULTING REFERRER		MDT DATE: 6/11/2024	Referrer: Mesi																						
SURNAME: Haney		CHI: 0209615214	Referring consultant: Mr M. Abdelsadg																						
FIRST NAME: James		Operating Consultant if post op:																							
<table border="1"> <tr> <th colspan="2">WHO PERFORMANCE STATUS</th> </tr> <tr> <td>0</td> <td>Fully active, able to on all pre disease performance without restriction.</td> </tr> <tr> <td>1</td> <td>Restricted in physically strenuous activity but ambulatory and able to carry out work of a light or sedentary nature.</td> </tr> <tr> <td>2</td> <td>Ambulatory and capable of self care but unable to carry out any work activities.</td> </tr> <tr> <td>3</td> <td>Capable of only limited self care, confined to bed or chair more than 50% of waking hours.</td> </tr> <tr> <td>4</td> <td>Completely disabled, cannot carry on any self care, totally confined to bed/chair.</td> </tr> <tr> <td>5</td> <td>Not recorded</td> </tr> </table>		WHO PERFORMANCE STATUS		0	Fully active, able to on all pre disease performance without restriction.	1	Restricted in physically strenuous activity but ambulatory and able to carry out work of a light or sedentary nature.	2	Ambulatory and capable of self care but unable to carry out any work activities.	3	Capable of only limited self care, confined to bed or chair more than 50% of waking hours.	4	Completely disabled, cannot carry on any self care, totally confined to bed/chair.	5	Not recorded	Patient in ward: Monklands/Ward 21									
WHO PERFORMANCE STATUS																									
0	Fully active, able to on all pre disease performance without restriction.																								
1	Restricted in physically strenuous activity but ambulatory and able to carry out work of a light or sedentary nature.																								
2	Ambulatory and capable of self care but unable to carry out any work activities.																								
3	Capable of only limited self care, confined to bed or chair more than 50% of waking hours.																								
4	Completely disabled, cannot carry on any self care, totally confined to bed/chair.																								
5	Not recorded																								
		REASON FOR REFERRAL: YES/NO																							
		PATHOLOGY REVIEW	RADIOLOGY REVIEW Y																						
		ONCOLOGY REVIEW Y	SURGICAL REVIEW Y																						
		Pre Op Performance:	1																						
		Post Op Performance:																							
CURRENT CLINICAL DETAILS:																									
63yr right handed Male with ?Left Parietal Lesion. Noticed lower right facial numbness on 30/10/24 and then facial weakness on 31/10/24. Also complains of right arm numbness and occasional slurring of speech for 2 days. Was admitted and evaluated for stroke. Otherwise Fit and Well. MRI showed suspicious left parietal lesion.																									
RELEVANT PAST MEDICAL & SURGICAL HISTORY:																									
BCC excised in 2010 from the nose, Clopidogrel																									
SECTION 2. TO BE COMPLETED BY COORDINATOR		Pathology Results																							
Presented by:		WHO grade:	INTEGRATED																						
Comment:			FINAL																						
Imaging Findings – SEE FORMAL REPORTS ON PORTAL																									
<table border="1"> <tr> <th>S ALA</th> <th>INTENTION OF SURGERY</th> <th>GTR</th> <th>BIOPSY</th> <th>DEBULKING</th> </tr> <tr> <td>LOCATION: Cranial/spinal/other:</td> <td></td> <td></td> <td></td> <td></td> </tr> <tr> <td>>80% resection enhancing component</td> <td></td> <td></td> <td></td> <td></td> </tr> <tr> <td>POSTERIOR FOSSA LESION</td> <td></td> <td></td> <td></td> <td></td> </tr> </table>		S ALA	INTENTION OF SURGERY	GTR	BIOPSY	DEBULKING	LOCATION: Cranial/spinal/other:					>80% resection enhancing component					POSTERIOR FOSSA LESION					<table border="1"> <tr> <th>Clinical Trial:</th> </tr> <tr> <td>Neuropsychology Referral</td> </tr> </table>		Clinical Trial:	Neuropsychology Referral
S ALA	INTENTION OF SURGERY	GTR	BIOPSY	DEBULKING																					
LOCATION: Cranial/spinal/other:																									
>80% resection enhancing component																									
POSTERIOR FOSSA LESION																									
Clinical Trial:																									
Neuropsychology Referral																									
MDT Discussion/Outcome																									
			Add to pending list:																						
Recommend interval imaging in six weeks* and follow up at Low Grade Clinic.																									
Approved By: Chairperson: Professor A. Chalmers		Imaging presented by: Dr N Fullerton & Dr S																							

Scanned Document
 13-May-2026 LIZMC
 Additional:Scanned Document

Filename: igprda202605131428560.pdf
 Extension:.tif
 Pages:

NHS Confidential: Personal data about a patient

www.nhslanarkshire.org.uk
 Medicine for Older Adults
 Secretary: 01698-752434

Dr S Findlay
 [REDACTED] Medical Centre
 2 Pollock Street
 Mossend
 Bellshill
 ML4 1QD

University Hospital
 Monklands
 Monkscourt Avenue
 Airdrie
 ML6 0JS

NHS
 Lanarkshire

Date Dictated: 12/11/2024
 Date Typed: 13/11/2024
 Ref: 3840830
 Letter Ref: FB/GT
 CHI Barcode:



Consultant: Dr [REDACTED]

Dear Dr Findlay

PatientName: James Haney
 Patientdate of birth: 02/09/1961
 PatientAddress: 9 Community Place, Bellshill, ML4 2DG

You will now be in receipt of an immediate discharge letter for James Haney - 02/09/61 who was admitted to hospital with a facial droop and dysarthria. He had a CT brain scan which was unremarkable. His MRI brain shows a small confluent focus of T2 signal in the posterior parietal lobe and the differential for it includes a primary glial tumour. He had an MRI with contrast, but this didn't really give us any clearer picture. He had a CT chest, abdomen and pelvis, which showed no evidence of malignancy. It's possible that the symptoms he presented with were seizure like, and if he develops any further seizure like symptoms it would be reasonable to start him on Keppra as per the BNF. He was seen by Neurology and was discussed at the Neuro Oncology MDT post discharge. I contacted them this week, and he is due to be seen in the Neurosurgical Outpatient Department on 10/12/24 for further investigation and follow-up, and I would hope that further information will be available from them.

Best wishes

Yours sincerely

Dr [REDACTED]
 Consultant in Medicine for Older Adults/Stroke Medicine

Authorised on 19/11/2024 11:25:15 by Dr [REDACTED]

Scanned Document
 13-May-2026 LIZMC
 Additional:Scanned Document

NHS Confidential: Personal data about a patient

Haney James

CHI: 0209615214

Clinic Letter

Dr. S Findlay
 [REDACTED] Medical Centre
 2 Pollock Street
 Mossend
 Bellshill
 ML4 1QD

Main
 Switchboard:
 Department:
 Contact Tel:
 Enquiries to:
 Letter Date:
 Reference:
 Dictated
 Date:
 Transcribed
 Date:

NHS
 Greater Glasgow
 and Clyde
 Queen [REDACTED] University Hospital
 1345 Govan Road
 Glasgow
 G51 4TF
 0141 201 1100
 Neurosurgery
 0141 201 2020
 Janice.Lafferty@ggc.scot.nhs.uk
 14/01/2025
 ROK/JL
 14/01/2025
 15/01/2025

Dear Dr. S Findlay,

James Haney; D.O.B: 02 Sep 1961; CHI: 0209615214
 9 COMMUNITY PLACE, Bellshill, Lanarkshire, ML4 2DG

Attendance: Specialty - Neurosurgery; Clinic - SUCCNS4.GENERIC GLIOMA TUES PM
 Date and Time of Appointment - 14/01/2025 15:00

Requested Out-patient Investigations:
 MRI April 2025

Follow Up: Review with results

Clinical Comments:

I reviewed James who was present with his [REDACTED] and [REDACTED]. From account of my own records he is a 63 year old right handed bar owner. His only past medical history includes resection of a basal ocell carcinoma back in 2010 from his left cheek area. He is currently not on any medication.

He is married with two children, non smoker only takes alcohol socially. He presented back in October/November last year with tingling which developed on the right side of his face and this then deteriorated to a bit of facial slumping. The next day he said he had some aches and pains over his body. These symptoms have slowly settled down and tend to have recovered, he does have a stick but he is only using this for reassurance now as opposed to functionally using it. He had an MRI back at that time and there was suggestion of a potential low grade lesion in the left parietal area.

He was discussed at the neuro-oncology MDT and we plan to repeat this imaging and also potential plan for potential surgical input with using functional MRI. We did repeat the imaging in December and thankfully this lesion appears to have got somewhat smaller particularly obvious on the flare sequence. I have shown the scans today and this would certainly not be in keeping with tumour behaviour and if anything is more suggestive of small ischaemia TIA type of event.

NHS Confidential: Personal data about a patient

Haney James

CHI: 0209615214

OPCL 14/01/2025 v1

I have circulated this letter to Dr [REDACTED] as I suspect there is not going to be much long term for neurosurgery. I did suggest to James that it was probably more likely TIA but I would leave this in the hands of the expertise over at Monklands Hospital and they can do the necessary follow up. I am simply going to repeat a scan in three months time and after that will review him in clinic and following this pattern I will discharge him from my care.

Kind regards

Yours sincerely,

Mr Roddy [REDACTED]

Consultant Neurosurgeon

Electronically Signed: Mr Roddy OKane, Consultant

cc. [REDACTED]
Consultant in Medicine for older
Adults in Stroke Medicine
Monklands Hospital
Monkscourt Avenue
ML6 OJS

Scanned Document
13-May-2026 LIZMC
Additional:Scanned Document

Filename: igprda202605131428490.pdf
Extension:.tif
Pages:

NHS Confidential: Personal data about a patient

Emergency Discharge Summary University Hospital Monklands



S Findlay
[Redacted] Medical Centre, 2 Pollock Street, Mossend, Bellshill
ML4 1GD

RE: HANEY, James. 9 Community Place . . Bellshill ML4 2DG

CH: 0209615214

Dear Doctor S Findlay ,

Your patient attended University Hospital Monklands on 28/01/2025 at 18:47

The presenting complaint was: back pain, arm shaking, slurred speech previous stroke same symptoms only other side

Diagnosis:

Diagnosis Notes:

Investigations:

Radiology Exams:

Procedures:

Medications:

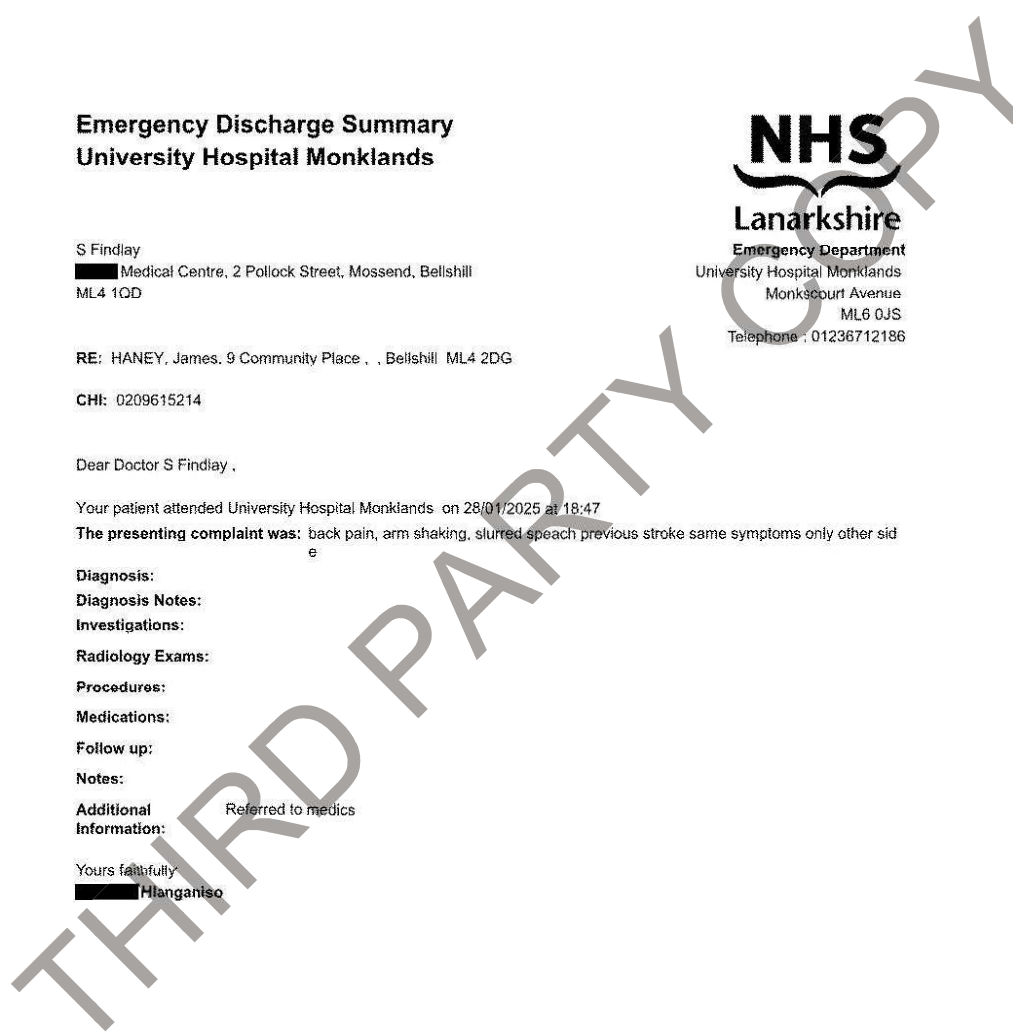
Follow up:

Notes:

Additional Information: Referred to medics

Yours faithfully

[Redacted] Hanganiso



Scanned Document
 13-May-2026 LIZMC
 Additional: Scanned Document

Filename: igprda202605131428470.pdf
 Extension: .tif
 Pages:

NHS Connecting People and Improving Lives

Monklands Hospital Monkscourt Avenue Airdrie ML6 0JS	Discharge Letter & Prescription
---	--

Page 1 of 1

To: S FINDLAY BRUCE MEDICAL CENTRE	Re: JAMES HANEY 9 COMMUNITY PLACE , BELLSHILL , LANARKSHIRE , ML4 2QG DOB: 02/09/1961 Hosp. No.: CHI No.: 0209615214
--	--

Date of Admission: 28/01/2025	Ward: ML MAU
Mode of Admission:	Consultant: Dr Raheel Syeed (RESPIRATORY MED-AQ)
Admission Reason:	
Discharge Date: 29/01/2025	Follow Up:

Pharmacy Dispensary screen only.

Clinical Progress Mr Haney presented with right sided twitching and speech slurring. This has been happening intermittently since admission in October however worsened the day before admission.

a follow up MRI in December showed a suspicious left parietal lesion. Neurologist Dr O'Keefe advised him that this was likely a stroke. He was to be started back on aspirin however this had not happened.

A CT head this admission showed no acute intracranial features and could not visualise the parietal lobe lesion.

Mr Haney is to be discharged with 2 weeks of 300mg Aspirin and atorvastatin 40mg

Mr Haney should hopefully be seen by the stroke team soon, however if not within 2 weeks can his GP please start him on clopidogrel when his aspirin is finished.

Medication Changes aspirin 300mg 2/52
 Atorvastatin 40mg

Allergy/intolerance	Reaction
No Known Drug Allergies	

Allergy records are as recorded at time and date of printing.

Drug	Dose	Route	Frequency	Duration	GP to continue
ASPIRIN 300 mg Dispersible Tablets	300 mg	Oral	ONCE daily at 7am	14 day(s)	N
ATORVASTATIN 40 mg Tablets	40 mg	Oral	ONCE daily at 10pm	L/T	Y

L/T = Long-term - Please note a minimum 7 day supply of medicines will be dispensed by the hospital pharmacy unless otherwise stated.

Discharged by: Dr Raheel Syeed

Scanned Document
 13-May-2026 LIZMC
 Additional: Scanned Document

Filename: igprda202605131428440.pdf
 Extension: .tif
 Pages:

NHS Confidential: Personal data about a patient


www.nhslanarkshire.org.uk
 Medicine for Older Adults
 01698 753678
 Allyson Ewart
 Medical Secretary

Dr [REDACTED] Hearn
 Medical Unit
 Monkscourt Avenue
 AIRDRIE
 ML6 0JS

University Hospital
 Monklands
 Monkscourt Avenue
 Airdrie
 ML6 0JS

NHS
 Lanarkshire

Date Dictated: 30/01/2025
 Date Typed: 30/01/2025
 Ref: 3900054
 Letter Ref: MB/ae
 CHI Barcode:



Consultant:

Dear Dr Hearn,

Patient Name: James Haney
 Patient date of birth: 02/09/1961
 Patient Address: 9 Community Place, Bellshill, ML4 2DG

You referred this gentleman to the Fast-track TIA clinic via workbench. We have seen him in the stroke service previously, and he has been extensively investigated. As far as I can see from the MRI reports in Glasgow, the suspicion is that this isn't a stroke. A glial tumour was raised as a possibility. It is possible that his symptoms represent seizures, and certainly in your referral you mention back pain and limb shaking which are the same symptoms as when we assessed him before (and decided he wasn't a stroke or TIA). It sounds as if he is having these stereotyped episodes very regularly, which again is unusual for stroke.

I think in view of all of this it seems extremely unlikely that this is a TIA or stroke that has been described. Perhaps referral to neurology is more appropriate, especially given that this has been happening regularly since October?

I will leave the action of this with yourself, but at the moment we haven't arranged a clinic review, as it doesn't seem like someone that should be seen in our service. Unfortunately, his notes haven't been scanned to portal to know which consultant was involved in their care. I'd be happy to discuss the case with them if needed.

Kind regards,
 Yours sincerely

[REDACTED]
 Consultant Geriatrician and Stroke Physician
 Honorary Professor at Glasgow Caledonian and Strathclyde Universities

Authorised on 30/01/2025 16:17:46 by [REDACTED]

(D) Dr S Findlay
 [REDACTED] Medical Centre
 2 Pollock Street
 Mossend
 Bellshill
 ML4 1QD

Scanned Document
 13-May-2026 LIZMC
 Additional: Scanned Document

Filename: igprda202605131428420.pdf
 Extension: .tif
 Pages:

NHS Confidential: Personal data about a patient

Emergency Discharge Summary University Hospital Monklands

NHS
Lanarkshire

Emergency Department
 University Hospital Monklands
 Monkscourt Avenue
 ML6 0JS
 Telephone : 01236712186

S Findlay
 Medical Centre, 2 Pollock Street, Mossend, Bellshill
 ML4 1GD

RE: HANEY, James. 9 Community Place . , Bellshill ML4 2DG

CH: 0209615214

Dear Doctor S Findlay ,

Your patient attended University Hospital Monklands on 19/02/2025 at 14:37

The presenting complaint was: eta 15:25, ED, ?side effects from medication, see clinical notes

Diagnosis: Personal Hist of Allergy to Other Drugs, Medicaments and Biol Substances

Diagnosis Notes:

Investigations:

Radiology Exams:

Procedures:

Medications:

Follow up:

Notes:

Additional Information: stroke symptoms Nov 2024, then thought to be glial tumour, neurosurgery after MRI and sequential CT now think is more likely stroke, started on atorvastatin and aspirin 3/52 ago, change to clopidogrel 5 days ago and since then: worsening dysarthria, fatigue, generalised itch, more restless and twitching in right arm, feels like worsening of stroke symptoms again. CT head, nad. bloods unremarkable. r/c home, STOP clopidogrel, back onto aspirin/referral made to TIA clinic as this was all cancelled initially when thought to be tumour

Yours faithfully
 McEwan

Scanned Document
 13-May-2026 LIZMC
 Additional:Scanned Document

Filename: igprda202605131428400.pdf
 Extension:.tif
 Pages:

NHS Lanarkshire Primary Care Operating Division OOH Call Incident Report

Call number:	64413	Receive Date:	19-Feb-2025 13:45
Patient's Name:	James Haney	Gender:	M
Date of birth:	2-Sep-1961 (63 years)	Current Address:	9 Community Place Bellsbill ML4 2DG
Address:	9 Community Place Bellsbill ML4 2DG		
Return Contact No:			
Tel No:	07794 268962		07794 268962
Mobile No:			
Priority:	Urgent	Call Origin:	NHS24
Received:	19-Feb-2025 13:45	Calltype:	Direct Referral ED
Advised:	14:14	Arrived PCC:	
Cons start:		Cons End:	

Consulting Doctor: Own doctor: ██████ Findlay

Reported Condition:
 ?SIDE EFFECTS FROM MEDICATION 3 DAYS

Followups:
 Attend ED

NHSD details:
 Disposition - Accident & Emergency (ASAP)

Scanned Document
 13-May-2026 LIZMC
 Additional:Scanned Document

Filename: igprda202605131428380.pdf

Extension:.tif

Pages:

NHS Confidential: Personal data about a patient


NHS Lanarkshire
www.nhs.uk/lanarkshire
 Medicine for Older Adults
 01698 753678
 Allyson Ewart
 Medical Secretary

Dr [REDACTED] McEwan
 GP in Emergency Department
 University Hospital Monklands
 AIRDRIE
 ML6 0JS

University Hospital
 Monklands
 Monkscourt Avenue
 Airdrie
 ML6 0JS



Date Dictated: 26/02/2025
 Date Typed: 26/02/2025
 Ref: 3922346
 Letter Ref: MB/ae
 Clinic Date: 25/02/2025
 CHI Barcode:



Consultant:

Prof [REDACTED]

Dear Dr McEwan

Patient Name: James Haney
Patient date of birth: 02/09/1961
Patient Address: 9 Community Place, Bellshill, ML4 2DG

You referred this gentleman to the Fast-track TIA clinic. He had been referred to us 3 weeks earlier, with symptoms that didn't sound like stroke or TIA, and we didn't see him at that stage for those reasons.

He has previously come through the stroke service, but we are confident he has not had a stroke. He does have an abnormal area on the left side of his brain. It doesn't reach the cortex. A small area of 'small vessel disease' is possible, but nothing that we would class as an ischaemic stroke. The possibility of a slow growing glial tumour has been raised as well, and he does seem to have some episodes of quite violent twitching of his right arm.

The reason you sent him back, I think was because you felt that he had some side-effects from his Clopidogrel. He presented to you 6 days ago. His main complaints were of constipation, visual blurring, increased sensitivity to sound and light. He says he gets stuttery occasionally at times. He thought it was all a side-effect of the Clopidogrel. You recommended switching from Clopidogrel to Aspirin, and since then he feels much better again.

His main issues today were his lower back pain and occasional uncontrolled right sided twitching. He is walking with an elbow crutch, but his gait actually seemed quite normal to me.

My impression is that this gentleman doesn't seem to have stroke disease. He may have a degree of small vessel disease. The symptoms that led to his presentation to you seemed to have been put down to his medication and have disappeared since he stopped taking Clopidogrel.

With his BP being 128/63, I don't think there is anything that we can offer him in the stroke service. I don't think he's had a stroke.

He does seem to be very anxious and has multiple other symptoms, but this is something that we can't really deal with in the Fast-track TIA clinic. I have discharged him today.

Kind regards,

Yours sincerely

Consultant Geriatrician and Stroke Physician
 Honorary Professor at Glasgow Caledonian and Strathclyde Universities

Authorised on 27/02/2025 12:40:26 by [REDACTED]

(D) Dr S Findlay

Scanned Document
13-May-2026 LIZMC
Additional:Scanned Document

Filename: igprda202605131428350.pdf
Extension:.tif
Pages:

NHS Confidential: Personal data about a patient

Emergency Discharge Summary
University Hospital Monklands



S Findlay
[Redacted] Medical Centre, 2 Pollock Street, Mossend, Bellshill
ML4 1GD

RE: HANEY, James. 9 Community Place . . Bellshill ML4 2DG

CH: 0209615214

Dear Doctor S Findlay ,

Your patient attended University Hospital Monklands on 09/03/2025 at 01:54

The presenting complaint was: ?stroke

Diagnosis:

Diagnosis Notes:

Investigations:

Radiology Exams:

Procedures:

Medications:

Follow up:

Notes:

Additional Information: referred to medics.

Yours faithfully
Tanveer Islam

THIRD PARTY COPY

Scanned Document
13-May-2026 LIZMC
Additional:Scanned Document

NHS Computer Personal data and system

Monklands Hospital Monkscourt Avenue Airdrie ML6 0JS	Discharge Letter & Prescription
--	--

page 1 of 2

To: S FINDLAY BRUCE MEDICAL CENTRE	Re: JAMES HANEY 9 COMMUNITY PLACE , BELLSHILL , LANARKSHIRE , ML4 2DG DOB: 02/09/1961 Hosp. No.: CHI No.: 0209615214
--	--

Date of Admission: 09/03/2025 **Ward:** ML Ward 17
Mode of Admission: Emergency **Consultant:** Dr Raheel [REDACTED] (RESPIRATORY MED-AQ)
Admission Reason: Right arm twitching and word finding difficulty
Discharge Date: 15/03/2025 **Follow Up:**

Pharmacy Dispensary screen only.

Clinical Progress Dear Colleague,

Mr James Haney was admitted to Monklands hospital with complaints of right arm twitching and word finding difficulty.

An MRI demonstrated Static appearances of left parietal subcortical lesion. No new findings.

Mr Haney was reviewed by neurology who would like his Kepra dose to be maintained. Mr Haney is to record a diary of these 'events' when they occur. The Neurology team will be organising an MRI and Lumbar puncture for Mr Haney in the near future.

Thank you for your ongoing care of this patient.

Ward 17 (Resp)
 Monklands Hospital

Medication Changes Patient advised stopped clopidogrel pre admission and was taking aspirin (from med rec).
 C/O levethracetam and folic acid.

Allergy/Intolerance	Reaction
***No Known Drug Allergies	

Allergy records are as recorded at time and date of printing.

Drug	Dose	Route	Frequency	Duration	GP to continue
ASPIRIN 75mg Soluble Tablets	75 mg	Oral	ONCE daily at 7am	L/T	Y

L/T = Long-term - Please note a minimum 7 day supply of medicines will be dispensed by the hospital pharmacy unless otherwise stated.

Discharged by: Dr Radia [REDACTED]

page1 of 2

THIS COMPANION FORM IS NOT TO BE USED

Monklands Hospital Monkscourt Avenue Airdrie ML6 0JS	Discharge Letter & Prescription
---	--

page 2 of 2

To: S FINDLAY BRUCE MEDICAL CENTRE	Re: JAMES HANEY 9 COMMUNITY PLACE , BELLSHILL , LANARKSHIRE , ML4 2DG DOB: 02/09/1961 Hosp. No.: CHI No.: 0209615214
--	--

Drug	Dose	Route	Frequency	Duration	GP to continue
ATORVASTATIN 40 mg Tablets	40 mg	Oral	ONCE daily at 10pm	Patient's Own	Y
FOLIC ACID 5 mg Tablets	5 mg	Oral	ONCE daily at 7am	LT	Y
LEVETIRACETAM 500 mg Tablets	500 mg	Oral	TWICE daily at 7am and 10pm	LT	Y

THIRD PARTY COPY

1. If it is a long-term medicine - Please note a minimum 7 day supply of medicines will be dispensed by the hospital pharmacy unless otherwise stated.

Discharged by: _____ Dr: _____ Radia: _____

page2 of 2

Scanned Document
 13-May-2026 LJZMC
 Additional:Scanned Document

Filename: igprda202605131428300.pdf
 Extension:.tif
 Pages:

NHS Confidential: Personal data about a patient

Haney James

CHI: 0209615214

Clinic Letter

Dr. S Findlay
 [REDACTED] Medical Centre
 2 Pollock Street
 Mossend
 Bellshill
 ML4 1QD

Main
 Switchboard:
 Department:
 Contact Tel:
 Enquiries to:
 Letter Date:
 Reference:
 Dictated
 Date:
 Transcribed
 Date:

NHS
 Greater Glasgow
 and Clyde
 Queen [REDACTED] University Hospital
 1345 Govan Road
 Glasgow
 G51 4TF
 0141 201 1100
 Neurosurgery
 0141 201 2020
 Enquiries to: Janice.Lafferty@ggc.scot.nhs.uk
 Letter Date: 05/08/2025
 Reference: ROK/JL
 Dictated: 05/08/2025
 Date:
 Transcribed: 06/08/2025
 Date:

Dear Dr. S Findlay,

**James Haney; D.O.B: 02 Sep 1961; CHI: 0209615214
 9 COMMUNITY PLACE, Bellshill, Lanarkshire, ML4 2DG**

Attendance: Specialty - Neurosurgery; Clinic - SUCCNS4-GENERIC GLIOMA TUES PM
 Date and Time of Appointment - 05/08/2025 15:45

Requested Out-patient Investigations:
 MRI within month

Follow Up: Review clinic 2 months October 2025

Clinical Comments:

James attended with his [REDACTED]. You will recall he presented to us last November with intermittent tremor of his right hand which was a new symptom and had imaging performed over at Monklands, imaging there suggested a potential low grade lesion in the left parietal area.

He was discussed at neuro-oncology MDT and we repeated imaging and some functional imaging to assess for potential surgery. The lesion had actually got a bit smaller particularly in volume flare sequences and it was actually felt that this more represented infarct. I had requested a repeat scan after this finding when I have reviewed in clinic in January. It seems now that he has had an MRI performed in Monklands and I am not exactly sure for what reason but the lesion is still present and they reported it as not significantly changed.

The PACS system was playing up at clinic and I was not able to fully get a grab and accurate assessment of all of these things today.

NHS Confidential: Personal data about a patient

Haney James

CHI: 0209615214

OPCL 05/08/2025 v1

His [REDACTED] tells me that he now has 6 to 8 weeks of headaches which is at the vertex, comes and goes exacerbated by noise and this is a new symptom along with the persisting right hand tremor. He was very anxious obviously and I think the most important thing is to get up to date imaging performed here at the Institute and I have put a request through for that to happen in the next 4 weeks.

Medication wise he takes a statin, Folic Acid, Leviteracetam and Aspirin.

I am planning to see him hopefully within the next 2 months once he has had his scan.

Kind regards

Yours sincerely,

Mr Roddy [REDACTED]

Consultant Neurosurgeon

Electronically Signed: Mr Roddy OKane, Consultant

cc.

Printed on 18/08/2025 16:50 by Janice Lafferty

Page 2 of 2

Scanned Document
13-May-2026 LIZMC
Additional: Scanned Document

Filename: igprda202605131428270.pdf
Extension: .tif
Pages:

NHS Confidential: Personal data about a patient

██████████ Houston
Multi Disciplinary Team Co-ordinator
6th Floor, Institute of Neurological Sciences
Southern General Hospital
1345 Govan Road
Glasgow G51 4TF

0141 232 7500
██████████ Houston@qgr.scot.nhs.uk

2025-SEPT-08.

DR ██████████
██████████ MEDICAL CENTRE
2 POLLOCK STREET
BELLSHILL
ML4 1QD

Dear DR ██████████

JAMES HANEY CHI: 0209615214
Neuro-oncology Patient Outcome

The above patient has been discussed at our Neuro-oncology MDT meeting on 2025-SEPT-03.

I have provided you with a copy of their outcome for your records and information.

This outcome can be influenced by subsequent review when appropriate communication will be forwarded by the relevant clinician as quickly as possible.

Yours sincerely,

██████████ Houston
MDT Co-ordinator

THIRD PARTY COPY

NHS Confidential: Personal data about a patient

INSTITUTE OF NEUROLOGICAL SCIENCES
Queen University Hospital.
 2025 Patient Referral Form for Neuro-oncology MDT

SECTION 1. TO BE COMPLETED BY REFERREER:		MDT DATE: : 03/09/2025	Referrer: [REDACTED]																								
SURNAME Haney		CHI: 0209615214	Referring consultant: [REDACTED]																								
FIRST NAME James		Operating Consultant if post op:																									
<table border="1"> <tr> <th colspan="2">WHO PERFORMANCE STATUS</th> </tr> <tr> <td>0</td> <td>Fully active, able to carry on all pre disease performance without restriction.</td> </tr> <tr> <td>1</td> <td>Restricted in physically strenuous activity but ambulatory and able to carry out work of a light or sedentary nature.</td> </tr> <tr> <td>2</td> <td>Ambulatory and capable of self care but unable to carry out any work activities.</td> </tr> <tr> <td>3</td> <td>Capable of only limited self care, confined to bed or chair more than 50% of waking hours.</td> </tr> <tr> <td>4</td> <td>Completely disabled, cannot carry on any self care, totally confined to bed/chair.</td> </tr> <tr> <td>9</td> <td>Not recorded</td> </tr> </table>		WHO PERFORMANCE STATUS		0	Fully active, able to carry on all pre disease performance without restriction.	1	Restricted in physically strenuous activity but ambulatory and able to carry out work of a light or sedentary nature.	2	Ambulatory and capable of self care but unable to carry out any work activities.	3	Capable of only limited self care, confined to bed or chair more than 50% of waking hours.	4	Completely disabled, cannot carry on any self care, totally confined to bed/chair.	9	Not recorded	<table border="1"> <tr> <td>REASON FOR REFERRAL:</td> <td>YES/NO</td> </tr> <tr> <td>PATHOLOGY REVIEW</td> <td></td> </tr> <tr> <td>ONCOLOGY REVIEW</td> <td></td> </tr> <tr> <td>RADIOLOGY REVIEW</td> <td>Yes</td> </tr> <tr> <td>SURGICAL REVIEW</td> <td>Yes</td> </tr> </table>		REASON FOR REFERRAL:	YES/NO	PATHOLOGY REVIEW		ONCOLOGY REVIEW		RADIOLOGY REVIEW	Yes	SURGICAL REVIEW	Yes
WHO PERFORMANCE STATUS																											
0	Fully active, able to carry on all pre disease performance without restriction.																										
1	Restricted in physically strenuous activity but ambulatory and able to carry out work of a light or sedentary nature.																										
2	Ambulatory and capable of self care but unable to carry out any work activities.																										
3	Capable of only limited self care, confined to bed or chair more than 50% of waking hours.																										
4	Completely disabled, cannot carry on any self care, totally confined to bed/chair.																										
9	Not recorded																										
REASON FOR REFERRAL:	YES/NO																										
PATHOLOGY REVIEW																											
ONCOLOGY REVIEW																											
RADIOLOGY REVIEW	Yes																										
SURGICAL REVIEW	Yes																										
<table border="1"> <tr> <td>Pre Op Performance:</td> <td>0</td> </tr> <tr> <td>Post Op Performance:</td> <td></td> </tr> </table>		Pre Op Performance:	0	Post Op Performance:																							
Pre Op Performance:	0																										
Post Op Performance:																											
CURRENT CLINICAL DETAILS: Has some headac 63 year old, right handed. Presented back in Nov 2024 with 7 glioma/? Stroke. Has been followed up radiologically due to uncertainty. Has some headache and persistent hand tremor. Can we review all imaging																											
RELEVANT PAST MEDICAL & SURGICAL HISTORY: BCC excised in 2010 from the nose, Clopidogrel																											
SECTION 2. TO BE COMPLETED BY COORDINATOR.		Pathology Results																									
Presented by: [REDACTED]		WHO grade:	INTEGRATED FINAL																								
Comment																											
Imaging Findings -																											
<table border="1"> <tr> <td>5 ALA</td> <td></td> </tr> <tr> <td>LOCATION: Cranial/spinal/other:</td> <td></td> </tr> <tr> <td>>90% resection enhancing component</td> <td></td> </tr> </table>		5 ALA		LOCATION: Cranial/spinal/other:		>90% resection enhancing component		<table border="1"> <tr> <td>Clinical Trial:</td> <td></td> </tr> <tr> <td>Posterior Fossa Lesion</td> <td></td> </tr> <tr> <td>Neuropsychology referral</td> <td></td> </tr> <tr> <td>Neurology referral</td> <td>YES</td> </tr> <tr> <td>Add to pending list</td> <td></td> </tr> </table>		Clinical Trial:		Posterior Fossa Lesion		Neuropsychology referral		Neurology referral	YES	Add to pending list									
5 ALA																											
LOCATION: Cranial/spinal/other:																											
>90% resection enhancing component																											
Clinical Trial:																											
Posterior Fossa Lesion																											
Neuropsychology referral																											
Neurology referral	YES																										
Add to pending list																											
<table border="1"> <tr> <td>INTENTION OF SURGERY:</td> <td>GTR</td> <td>BIOPSY</td> <td>DB</td> </tr> <tr> <td></td> <td></td> <td></td> <td></td> </tr> </table>		INTENTION OF SURGERY:	GTR	BIOPSY	DB																						
INTENTION OF SURGERY:	GTR	BIOPSY	DB																								
MDT Discussion/Outcome																											
For close follow up in three months.																											
Approved By: Chairperson: Mr A Grivas		Imaging presented by: Dr N Fullerton																									

THIRD PARTY COPY

Scanned Document
 13-May-2026 LIZMC
 Additional: Scanned Document

Filename: igprda202605131428240.pdf
 Extension: .tif
 Pages:

NHS Confidential: Personal data about a patient

Haney James

CHI: 0209615214

Clinic Letter

Dr. S Findlay
 [REDACTED] Medical Centre
 2 Pollock Street
 Mossend
 Bellshill
 ML4 1QD

Main
 Switchboard:
 Department:
 Contact Tel:
 Enquiries to:
 Letter Date:
 Reference:
 Dictated
 Date:
 Transcribed
 Date:

NHS
 Greater Glasgow
 and Clyde
 Queen [REDACTED] University Hospital
 1345 Govan Road
 Glasgow
 G51 4TF
 0141 201 1100
 Neurology
 0141-232-7542
 [REDACTED] Scot
 18/11/2025
 VF/CM
 18/12/2025
 29/12/2025

Dear Dr. S Findlay,

James Haney; D.O.B: 02 Sep 1961; CHI: 0209615214
 9 COMMUNITY PLACE, Bellshill, Lanarkshire, ML4 2DG

Attendance: Specialty - Neurology; Clinic - SUVFENE401D-DR V FENECH NEURO ONC TUES PM
 Date and Time of Appointment - 18/11/2025 15:00

Clinical Comments:**Diagnosis**

1. Left parietal region abnormality - under active imaging surveillance by neurosurgeon Mr [REDACTED]
2. Intermittent right-sided arm movements and speech disturbance - appears functional/non-epileptic in nature on video captured by family

Current anti-seizure medication:

1. Kepra 500mg BD

Recommendations

1. Please gradually withdraw Kepra by 250mg every week until completely discontinued. If during the weaning process he experiences any worsening of symptoms, he should contact Dr [REDACTED] secretary and try to capture further videos
2. Please start trial of propranolol as a migraine prophylaxis as per instructions below.

Printed on 31/12/2025 13:32 by [REDACTED] McLoughlin

Page 1 of 5

NHS Confidential: Personal data about a patient

Haney James

CHI: 0209615214

OPCL 18/11/2025 v1

3. Counselling regarding medication overuse including avoiding the use of co-codamol and other opiate-containing medication for headache management

Outpatient plan

1. Referral to Neuropsychology team in Lanarkshire for additional support

Follow up

1. He will be followed up by consultant neurologist Dr [REDACTED] in Lanarkshire

Comments

I reviewed Mr Haney, who attended the neurology clinic accompanied by his [REDACTED] and [REDACTED] on the 18th November 2025.

Mr Haney is a 64 year old right-handed gentleman who was referred for neurology review from the neuro-oncology MDT on the 23rd September 2025 in view of an "intermittent right-hand tremor" of unclear aetiology. I had originally planned to see him at a joint appointment with Dr [REDACTED] who had previously reviewed him at Monklands Hospital, however he did not attend that appointment and was subsequently booked into my clinic today by the appointments team.

He was initially admitted to Monklands Hospital between the 23rd October 2024 and the 1st November 2024. He presented after developing evolving neurological symptoms. The day before admission, he felt unwell at work and started to notice a tingling sensation over the right side of his face like he had been to the dentist. After he returned home, his family also noted a possible right-sided facial droop. The next morning, he also developed some speech disturbance which consisted of word-finding difficulties. Later that day at work, he then developed altered sensation and pain affecting the right side of his body including neck, arm, flank, back, and leg.

On admission, he was documented to have mild speech disturbance, right arm power 4/5 with subjective sensory change, and limited assessment of the right leg due to ongoing pain. His blood tests were unremarkable and a CT head showed no acute intracranial abnormality. He was initially treated as a possible TIA/minor stroke. However, subsequent MRI brain demonstrated a small focus of confluent T2 signal in the posterior parietal lobe with a broad differential. A CT CAP showed no evidence of malignancy.

During the admission, he was reviewed by consultant neurologist Dr [REDACTED] who noted some patchy, inconsistent sensory disturbance on the right side without other focal deficits. Given his imaging raised concern for a possible glial lesion, his case was discussed with on-call neurosurgical team, who

Printed on 31/12/2025 13:32 by [REDACTED] McLoughlin

Page 2 of 5

NHS Confidential: Personal data about a patient

Haney James

CHI: 0209615214

OPCL 18/11/2025 v1

recommended referral for discussion at the neuro-oncology MDT in due course. There was also a mention of a history of intermittent right arm movements, which Mr Haney reports started during this admission, and in this context, consideration was given to commence levetiracetam if there was concern for seizure activity. However, this was not started at the time, and as he was clinically stable at the time, he was discharged home.

He was re-admitted to Monklands Hospital between the 9th and 14th March 2025 with movements affecting the right arm and word-finding difficulties. Mr Haney described that he had been at the pub when he developed a headache and started to feel increasingly anxious and overwhelmed in a loud environment. He felt his body was shutting down and he was unable to cope and had his employee ring his wife to collect him. When she arrived, she found him shaking all over and unable to speak other than one word answers, such as "home".

He was taken to hospital and in the Emergency Department, he was able to mouth words, write, nod, and gesture appropriately despite very limited verbal output. He also had some shaking movements of his right arm. His blood tests were unremarkable and a CT head and CT angiogram did not reveal any acute intracranial abnormality. He was commenced on Keppra. During the admission, he was also reviewed by the speech language pathologist who noted hesitant and dysfluent speech which then became fluent when he was distracted, suggestive of a functional speech disorder. An updated MRI head with contrast on the 13th March 2025 showed no interval change compared with previous. He was reviewed again by Dr [redacted] on the 14th March 2025 and given the diagnostic uncertainty regarding the lesion and these episodes, he was discharged home on Levetiracetam 500mg twice daily.

During this time, I note that his case has been extensively discussed at the neuro-oncology MDT on more than one occasion, and he has also undergone various scans including functional MRI and MR spectroscopy, and that the lesion appears essentially static on his most recent scan from the 17th November 2025. My understanding is that the overall likelihood is that the lesion probably favours focal cortical dysplasia. However, he remains under the care of Mr [redacted] from the neurosurgery perspective who is planning to do further imaging for him in a couple of months.

Speaking to Mr Haney in clinic today, he describes experiencing intermittent shaking episodes of the right arm, which sound variable in character, ranging from brief "tic-like" movements of the shoulder to more forceful shaking of the entire arm. Episodes can occur during the day and while lying awake at night, but never from sleep. He will usually put objects down to avoid dropping them when the movements start. Some episodes are brief and isolated, and others can last for several minutes. During more intense episodes, his speech can become affected and he can develop associated word-finding difficulties. He retains awareness throughout and does not come to harm during them. There is no associated pain and no features to suggest a generalised tonic-clonic seizure.

The family showed me a video of a typical episode of right upper limb shaking associated with speech disturbance. In the video, the movements of the right arm appear non-stereotyped, with variable rhythm and distractable, and his speech is stuttering. Interestingly, his family reported a perceived association

NHS Confidential: Personal data about a patient

Haney James

CHI: 0209615214

OPCL 18/11/2025 v1

with stress, including ongoing [REDACTED] conflict and psychosocial stressors related to a [REDACTED] who suffers from bipolar disorder. However, I did not have the opportunity to explore this in further detail.

In addition, Mr Haney also mentioned intermittent episodic headaches which have been ongoing since October 2024, occurring approximately 5 to 6 times per month. These are described as severe, generalised or temporal headaches with a dull, pressure-like quality, sometimes associated with phonophobia and a preference to lie in a dark room but without nausea or vomiting. He has been using regular co-codamol for symptomatic relief.

He [REDACTED] home with his [REDACTED] and [REDACTED]. He is a pub and restaurant owner. He is a non-driver. He is a non-smoker and drinks 3 to 4 beers a few times per week. He denies any significant family history.

Examination

His neurological examination was completely intact and I did not observe any evidence of abnormal movements or tremor during my assessment today. His blood pressure was 139/86mmHg.

Discussion and Management Plan

The video recording that Mr Haney and his family showed me in clinic today does not appear to be consistent with epileptic seizure activity but rather the semiology appears functional/non-epileptic in nature. I discussed this in detail with him and his family, including an explanation of dissociative/non-epileptic episodes and how these differ from epileptic seizures. I signposted him to the Dissociative app on the NHS Right Decisions Website for further reading.

I also explained that we would not typically treat these episodes with anti-seizure medication and that treatment with Keppra is therefore unlikely to be beneficial. **In view of this, I would be grateful if you could withdraw his Keppra by 250mg once weekly until it is discontinued.** If he develops any worsening or new symptoms during the weaning process, I have advised him that he should contact us through Dr [REDACTED] secretary in Lanarkshire and to try and capture further videos. I will additionally refer him to the neuropsychology team in Lanarkshire for further support, as they should be able to undertake more focused work to help him develop strategies to manage and reduce these episodes.

In relation to the headaches, I discussed with him and his family that they sound migrainous in quality and suggested a trial of a preventative medication with propranolol, which may be beneficial not only for headache prevention but also for any comorbid anxiety and tremor symptoms. **Therefore, I would be grateful if you could please start propranolol at 20mg twice daily and gradually increase every 2 weeks till target daily dose of 80mg twice daily provided no side effects or highest maximum tolerated dose. Judgement of efficacy should be made after being on the target dose or highest tolerated dose at 3 months. If the preventative medication is ineffective at 3 months, please wean**

Printed on 31/12/2025 13:32 by [REDACTED] McLoughlin

Page 4 of 5

NHS Confidential: Personal data about a patient

Haney James

CHI: 0209615214

OPCL 18/11/2025 v1

to discontinue and we can consider an alternative medication. I also discussed the importance of avoiding co-codamol for headache management and counselled him regarding the risk of medication overuse headache.

I discussed his case with both consultant neurologist Dr Molinari and Dr [REDACTED]. He has been discharged from this clinic and will continue to be followed up in Lanarkshire under Dr [REDACTED].

Kind regards,

Dr [REDACTED] Fenech

ST6 Neurology registrar

Electronically Signed: Dr [REDACTED] Fenech, Consultant

cc.

Dr [REDACTED] Consultant Neurologist
Third Floor, Neurology Building
Queen [REDACTED] University Hospital
1345 Govan Road
Glasgow
G51 4TF

Printed on 31/12/2025 13:32 by [REDACTED] McLoughlin

Page 5 of 5

Scanned Document
13-May-2026 LIZMC
Additional:Scanned Document

Filename: igprda202605131428170.pdf
Extension:.tif
Pages:

NHS Confidential: Personal data about a patient

Haney James

CHI: 0209615214

Clinic Letter

Dr. S Findlay
 [REDACTED] Medical Centre
 2 Pollock Street
 Mossend
 Bellshill
 ML4 1QD

Main
 Switchboard:
 Department:
 Contact Tel:
 Enquiries to:
 Letter Date:
 Reference:
 Dictated
 Date:
 Transcribed
 Date:

NHS
 Greater Glasgow
 and Clyde
 Queen [REDACTED] University Hospital
 1345 Govan Road
 Glasgow
 G51 4TF
 0141 201 1100
 Neurosurgery
 0141 201 2020
 Janice.Lafferty@nhs.scot
 25/11/2025
 ROK/JL
 25/11/2025
 04/12/2025

Dear Dr. S Findlay,

James Haney; D.O.B: 02 Sep 1961; CHI: 0209615214
9 COMMUNITY PLACE, Bellshill, Lanarkshire, ML4 2DG

Attendance: Specialty - Neurosurgery; Clinic - SUCCNS4-GENERIC GLIOMA TUES PM
 Date and Time of Appointment - 25/11/2025 15:45

Follow Up: Glioma Clinic June 2026

Clinical Comments:

I reviewed James who was presented with his [REDACTED] and his [REDACTED]. You will recall we were following up a left parietal lobe lesion and we were unsure as to the exact abnormality, it was discussed at the last neuro-oncology MDT and the differential diagnosis in order was of cortical dysphasia/low grade glioma/infarction. I am pleased to report that the most recent scan on the 17th November has not revealed any progression to the left cortical lesion. I have reassured them that I am now less suspicious that this could be low grade or any type of tumour but I think just for completeness sake we will organise for a repeat scan around 6 months time i.e May/June next year. I note he has also to see neurology in December. I will see him once we have repeated this scan in mid point next year.

Kind regards

Yours sincerely,

Mr Roddy [REDACTED]

Printed on 11/12/2025 09:57 by Janice Lafferty

Page 1 of 2

NHS Confidential: Personal data about a patient

Haney James

CHI: 0209615214

OPCL 25/11/2025 v1

Consultant Neurosurgeon

Electronically Signed: Mr Roddy OKane, Consultant

cc.

THIRD PARTY COPY

Printed on 11/12/2025 09:57 by Janice Lafferty

Page 2 of 2

Scanned Document
13-May-2026 LJZMC
Additional:Scanned Document

Filename: igprda202605131428140.pdf
Extension:.tif
Pages:

NSI Compliance Platform developed by pml

HANEY, James (Mr) - 0209615214 (CHI)

e0cc8a09-fe7b-4d9c-b3e0-6c36feff152e

HANEY, James (Mr)

BORN 02-Sep-1961 (64y) GENDER Male
CHI 0209615214

Request to GP to prescribe medication

Last updated by Valentina FENECH [redacted] Fenech) on 12-Dec-2025 17:14 (v. 1)

Content Restricted No Yes
Sensitivity Sensitive Sensitive
If the information on this form merits further restriction than that of Highly Sensitive, please select Yes to apply a Privacy Seal
The information on this form will be viewable by health and care providers with the appropriate access permissions

Date 12-Dec-2025
Hospital Queen [redacted] University Hospital Other
Specialty / Service Neurology
Clinic Yes Please Specify

Dear Doctor

Your Patient Was

Please Prescribe

Urgent / Routine Routine - prescription available 48 hours following request
Indication migraine type headaches

Additions and Replacements

Product	Dose	Frequency	Current Regime Status	Comments
propranolol	20mg	twice daily	Addition	Please start propranolol at 20mg twice [redacted] and gradually increase every 2 weeks till target daily dose of 80mg twice daily provided no side effects or highest maximum tolerated dose. Judgment of efficacy should be made after being on the target dose or highest tolerated dose at 3 months. If the migraine prophylactic is ineffective at 3 months, please wean to discontinue and we can consider alternative prophylactic agent.

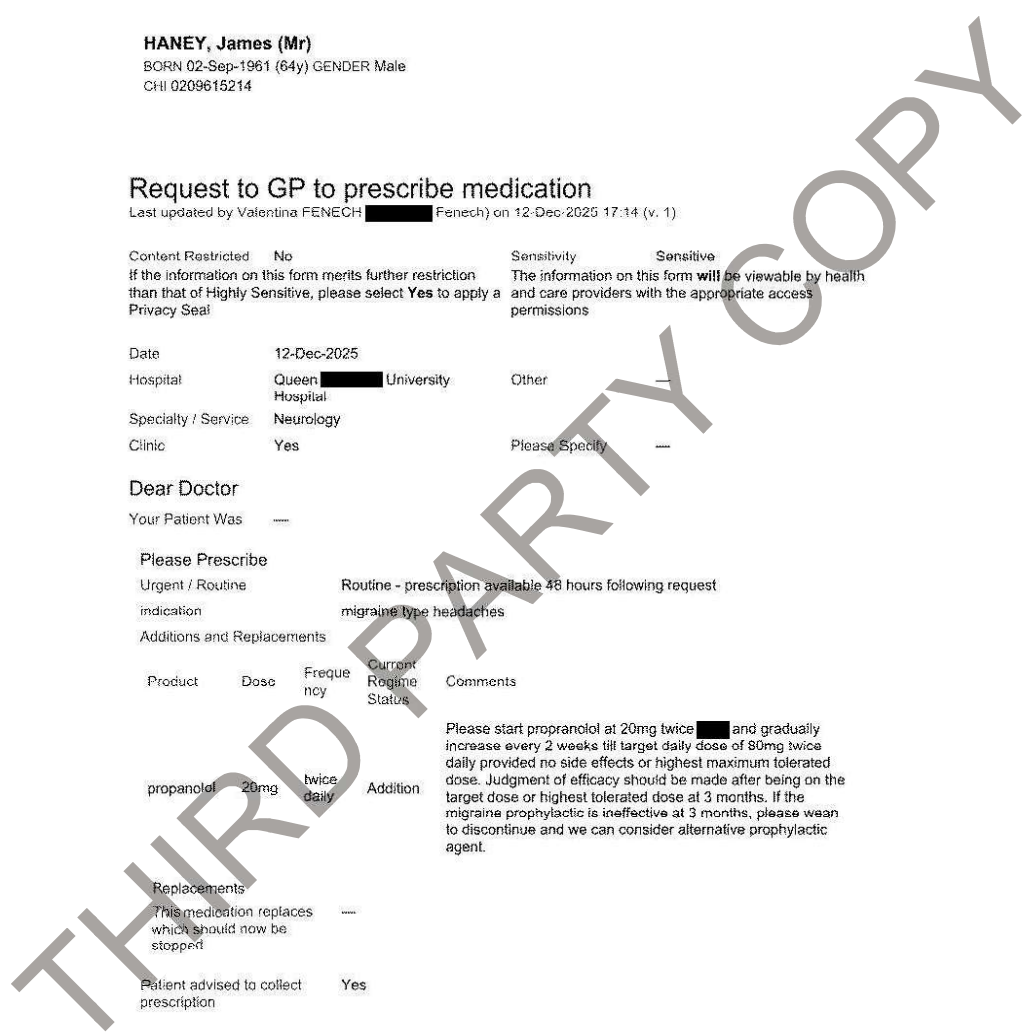
Replacements

This medication replaces which should now be stopped

Patient advised to collect prescription Yes

Generated by [redacted] FENECH on 12-Dec-2025 17:14

Page 1 of 2



NHS Computer Personal Data and System

HANEY, James (Mr) - 0209615214 (CHI)

e0cc8a09-fe7b-4d9c-b3e0-6c36feff152e

Please Note: A Detailed Letter Will Follow.

Additional Notes / Summary

Additional Notes / Summary

When you click to 'Complete' a summary of the the form will be sent electronically to the registered GP practice.

Clinician Details

Name	██████████ Fenech
ClinicianDetailsRole	Doctor
Professional Registration Number	7809866
Contact Details	██████████ fenech2@nhs.scot

THIRD PARTY COPY

Generated by ██████████ FENECH on 12-Dec-2025 17:14

Page 2 of 2

Scanned Document
13-May-2026 LIZMC
Additional:Scanned Document

Filename: igprda202605131428090.pdf
Extension:.tif
Pages:

NHS Confidential: Personal data about a patient

Haney James

CHI: 0209615214

Referral letter:

Department of Neuropsychology
University Hospital Monklands
Monkscourt Avenue
Airdrie
ML6 6JS

Main Switchboard:
Department:
Contact Tel:
Enquiries to:
Letter Date:
Reference:
Dictated Date:
Transcribed Date:

NHS
Greater Glasgow
and Clyde

Queen ██████ University Hospital
1345 Govan Road
Glasgow
G51 4TF
0141 201 1100
INS Neurology
0141 232 7938
████████@nhs.scot
29/01/2026
VFTR
18/12/2025
23/01/2026

Dear Colleague,

James Haney; D.O.B: 02/09/1961; CHI: 0209615214
9 COMMUNITY PLACE, Bellshill, Lanarkshire, ML4 2DG

I would be very grateful for your kind input of this 64 year old right-handed gentleman who I reviewed at the neurology clinic.

He has a history of a left parietal region abnormality which has been extensively investigated and discussed at the Neuro-Oncology MDT in Glasgow, with the most likely differential being an area of focal cortical dysplasia. However, he remains under active imaging surveillance by Consultant Neurosurgeon Mr ██████ at the QEUH INS.

He was referred for neurological assessment in view of a history of right-sided upper limb movements of uncertain aetiology. Prior to attending clinic, he had previously been initiated on Keppra due to concerns that these movements represented focal seizure activity. However, following review at clinic, including review of one of the episodes captured on video, this ██████ appears to be in-keeping with non-epileptic attack/functional diagnosis.

I have explained this to him and signposted him to the Dissociative App on the NHSGGC Right Decisions website for further information. I have also recommended that we gradually reduce the Keppra to stop and that he is initiated on a trial of propranolol to manage his headaches, anxiety and tremor.

I suspect he may struggle to engage with the diagnosis and self-management of the condition, and I feel he would benefit from Neuropsychology input to explore additional strategies to help him deal with these episodes. Although I have reviewed him at a clinic in Glasgow, he will be followed up by Consultant Neurologist Dr ██████ in Lanarkshire.

Printed on 29/01/2026 15:38 by ██████ McLoughlin

Page 1 of 2

NHS Confidential: Personal data about a patient

Haney James

CHI: 0209615214

GCL 18/12/2025 v1

Thank you for your consideration with this referral. I have enclosed my clinic letter with full details on the case but please do not hesitate to get in touch with me in the interim should you require any additional information.

Kind regards,

██████████ Fenech

ST6 Neurology Registrar

Enc: Clinical letter dated 18/12/25

Electronically Signed: Dr ██████████ Fenech, Consultant

cc. Dr Molinari
Consultant Neurologist
INS Neurology
QEUH

.

.

.

.

.

Dr ██████████ Miller
Consultant Neurologist
University Hospital Hairmyres
Eaglesham Road
Glasgow
G75 8RD

THIRD PARTY COPY


Printed on 29/01/2026 15:38 by ██████████ McLoughlin

Page 2 of 2

Scanned Document
13-May-2026 LIZMC
Additional:Scanned Document

Filename: igprda202605131428070.pdf
Extension:.tif
Pages:

NHS [REDACTED] Personal data about a patient



Neuropsychology Service
University Hospital Monklands
Monkscourt Avenue
Airdrie
ML6 0JS
www.nhslanarkshire.co.uk

CONFIDENTIAL
James Haney
9 Community Place
Bellshill
ML4 2DG

Date: 05/02/2026
Our Ref: AW/NF
Enquiries: Psychology Secretary
Direct Line: 01698 752390

Dear James Haney (CHI: 0209615214)

As you will be aware, [REDACTED] Fenech, ST6 Neurology Registrar has referred you to the Neuropsychology Service for an assessment appointment.

The purpose of this letter is to confirm whether you wish your name to be placed on our waiting list.

If you **do not want** your name to be placed on the list, **you do not need to take any action**. Your name will *not* be placed on the waiting list and we will inform your referrer of your decision.

If you **want** your name to be placed on the list, **please contact us within 14 days from the date at the top of this letter**.

You can contact us:

- by telephone on 01698 752390 (please also give information asked for on enclosed sheet)
- or
- by returning the enclosed information sheet


If you opt-in, you may be contacted by our service to obtain additional information - this phone call will last approximately 30 minutes and helps us to clarify your needs.

Yours sincerely

Secretary
Neuropsychology Service



NHS Confidential: Personal data about a patient



(D) Dr S Findlay
[redacted] Medical Centre
2 Pollock Street
Mosend
Bellshill
ML4 1QD

(P) Dr [redacted] Fenech
Neurology Registrar
Institute of Neurological Sciences
Queen [redacted] University Hospital
G51 4TH

THIRD PARTY COPY



NHS Confidential: Personal data about a patient



University for the Common Good
 of Health and Life Sciences



PLEASE COMPLETE AND RETURN

Name (Please print): James Haney
Date of Birth: 02/09/1961
Contact Telephone Number:
Address:

- I wish my name to be placed on the NEUROPSYCHOLOGICAL SERVICE waiting list for an assessment appointment.

Signed : _____

- I am agreeable to being contacted by phone when an appointment becomes available YES / NO
 (Please ensure a contact telephone number is provided above)
- A message can be left on my answer machine YES / NO
- A message can be left with whoever answers YES /NO

All Lanarkshire libraries now have a healthy reading section with a wide range of mental health and well-being self-help leaflets, books, CDs, DVDs and web-based support. Lanarkshire Psychological Services has a helpful website: www.lanarkshiremindmatters.scot.nhs.uk. The site is designed to provide self-help information, access to course and online CBT resources, and enable patients to sign up for anxiety management programmes. The Calm Distress programme, is also available via the website.


Should you need help urgently or if your mental health problems persist please contact your GP or out of hours NHS24 on 111. The following agencies may also help: Breathing Space - 0800 83 85 87 (evenings and weekends) www.breathingspacescotland.co.uk or Samaritans -116 123 (24hrs) www.samaritans.org



Scanned Document
 13-May-2026 LIZMC
 Additional:Scanned Document

Filename: igprda202605131428040.pdf
 Extension:.tif
 Pages:

NHS Confidential: Personal data about a patient



Neuropsychology Service
University Hospital Monklands
Monkscourt Avenue
Airdrie
ML6 0JS
www.nhslanarkshire.co.uk

CONFIDENTIAL

James [redacted]
9 Community Place
Bellshill
ML4 2DG

Date: 05/02/2026
Our Ref: AW/NF
Enquiries: Psychology Secretary
Direct Line: 01698 752390

Dear James Haney (CHI: 0209615214)

As you will be aware, [redacted] Fenech, ST6 Neurology Registrar has referred you to the Neuropsychology Service for an assessment appointment.

The purpose of this letter is to confirm whether you wish your name to be placed on our waiting list.

If you **do not want** your name to be placed on the list, you **do not need to take any action**. Your name will **not** be placed on the waiting list and we will inform your referrer of your decision.

If you want your name to be placed on the list, please contact us within 14 days from the date at the top of this letter.

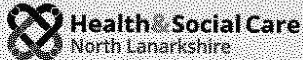You can contact us:

- by telephone on 01698 752390 (please also give information asked for on enclosed sheet)
- or
- by returning the enclosed information sheet.

If you opt-in, you may be contacted by our service to obtain additional information - this phone call will last approximately 30 minutes and helps us to clarify your needs.

Yours sincerely

Secretary
Neuropsychology Service



NHS Confidential. Please do not share with a patient



University for the Common Good

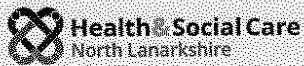█ of Health and Life Sciences



(D) Dr S Findlay
Bruce Medical Centre
2 Pollock Street
Mossend
Bellshill
ML4 1QD

(P) Dr █ Fenech
Neurology Registrar
Institute of Neurological Sciences
Queen █ University Hospital
G51 4TH

THIRD PARTY COPY



NHS Confidential: Personal data about a patient



University for the Common Good
 of Health and Life Sciences



PLEASE COMPLETE AND RETURN

Name (Please print): James Haney
Date of Birth: 02/09/1961
Contact Telephone Number:
Address:

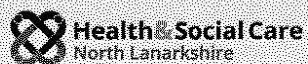- I wish my name to be placed on the NEUROPSYCHOLOGICAL SERVICE waiting list for an assessment appointment.

Signed _____

- I am agreeable to being contacted by phone when an appointment becomes available YES / NO
 (Please ensure a contact telephone number is provided above)
- A message can be left on my answer machine YES / NO
- A message can be left with whoever answers YES / NO

All Lanarkshire libraries now have a healthy reading section with a wide range of mental health and well-being self-help leaflets, books, CDs, DVDs and web-based support. Lanarkshire Psychological Services has a helpful website: www.lanarkshiremindmatters.scot.nhs.uk. The site is designed to provide self-help information, access to course and online CBT resources, and enable patients to sign up for anxiety management programmes. The Calm Distress programme, is available via the website.

Should you need help urgently or if your mental health problems persist please contact your GP or out of hours NHS24 on 111. The following agencies may also help. Breathing Space - 0800 83 83 87 (evenings and weekends) www.breathingspacescotland.co.uk or Samaritans - 116 123 (24hrs) www.samaritans.org



Scanned Document
13-May-2026 LIZMC
Additional:Scanned Document

Filename: igprda202605131427570.pdf
Extension:.tif
Pages:

NHS Confidential: Personal data about a patient

Haney James

CHI: 0209615214

Clinical letter - Others:

Dr [REDACTED] Miller
Consultant Neurologist
QEUH
INS

Main Switchboard:
Department:
Contact Tel:
Enquires to:
Letter Date:
Reference:
Dictated Date:
Transcribed Date:

NHS
Greater Glasgow
and Clyde

Queen [REDACTED] University Hospital
1345 Govan Road
Glasgow
G5 1 4TF
0141 201 1100
Neurology
0141 232 7938
[REDACTED] Ramage@nhs.scot
23/02/2026
VF/LC
27/01/2026
19/02/2026

Dear Dr [REDACTED],

James Haney; D.O.B: 02/09/1961; CHI: 0209615214
9 COMMUNITY PLACE, Bellshill, Lanarkshire, ML4 2DG

Thank you for accepting to review this patient at your outpatient clinic in Lanarkshire.

He is a 64 year old right-handed gentleman with a history of right-sided upper limb movements and speech disturbance on a background of left parietal region abnormality which has been extensively investigated and discussed at the Neuro-Oncology MDT in Glasgow.

During clinic review one of the episodes captured on video appears to be in-keeping with a non-epileptic/functional diagnosis. He is currently on a weaning regime of Keppra and has been referred to Neuropsychology for additional support. He has also been commenced on a trial of Propranolol to manage his headaches, anxiety and tremor. I have attached my clinic letter from the 18th November 2025 with full details of the case.

Kind regards,

Dr [REDACTED] Fenech
ST6 Neurology Registrar

Encs: Clinic Letter 18.11.25

Electronically Signed: Dr [REDACTED] Fenech, Consultant


cc. Dr Molinari
Consultant Neurologist
QEUH
INS

Printed on 23/02/2026 07:57 by [REDACTED] McLoughlin

Page 1 of 1

Scanned Document
13-May-2026 LIZMC
Additional:Scanned Document

NHS Confidential: Personal data about a patient



Neuropsychology Service
University Hospital Monklands
Monkscourt Avenue
Airdrie
ML6 0JS
www.nhslanarkshire.co.uk

CONFIDENTIAL
Dr [REDACTED] Fenech
Neurology Registrar
Institute of Neurological Sciences
Queen [REDACTED] University Hospital
G51 4TH

Date: 06/03/2026
Our Ref: AW/NF
Enquiries: Psychology Secretary
Direct Line: 01698 752390

Dear Dr Fenech

Re: James Haney DOB: 02/09/1961 CHI: 0209615214

You referred the above person recently to our service and I wrote asking if they wished to be placed on our waiting list. There was no response to this letter therefore James Haney has now been discharged from this team.

Yours sincerely


Dr [REDACTED]
Consultant Clinical Psychologist/Clinical Lead for Neuropsychology

All Lanarkshire libraries now have a healthy reading section with a wide range of mental health and well-being self-help leaflets, books, CDs, DVDs and web-based support. Lanarkshire Psychological Services has a helpful website: www.lanarkshiremindmatters.scot.nhs.uk. The site is designed to provide self-help information, access to course and online CBT resources, and enable patients to sign up for anxiety management programmes. The Gabn Distress programme is also available via the website.

Should you need help urgently or if your mental health problems persist please contact your GP or out of hours NHS24 on 111. The following agencies may also help: Breathing Space - 0800 83 85 87 (evenings and weekends) www.breathingspacescotland.co.uk or Samaritans -116 123 (24hrs) www.samaritans.org



NHS Confidential: Personal data about a patient



(D) Dr S Findlay
[redacted] Medical Centre
2 Pollock Street
Mosscend
Bellshill
ML4 1QD

(P) James Haney
9 Community Place
Bellshill
ML4 2DG

THIRD PARTY COPY



Scanned Document
 13-May-2026 LIZMC
 Additional: Scanned Document

Filename: igprda202605131427520.pdf
 Extension: .tif
 Pages:

NHS Confidential: Personal data about a patient

Haney James

CHI: 0209615214

Letter to Patient:

James Haney
 9 COMMUNITY PLACE
 Bellshill
 Lanarkshire
 ML4 2DG

Main Switchboard: 0141 201 1100
 Department: Neurology
 Contact Tel: 0141 232 7938
 Enquiries to: Ramage
 Letter Date: 11/05/2026
 Reference: VF/EP
 Dictated Date: 17/03/2026
 Transcribed Date: 07/05/2026

NHS
 Greater Glasgow
 and Clyde
 Queen University Hospital
 1345 Govan Road
 Glasgow
 G51 4TF

Dear Mr Haney,

I have been notified by the neuropsychology team in Ayrshire that they had recently written to you to see if you wish to be placed on their waiting list. However, as they did not hear back from you, you have been discharged by their service. If you are still interested in being seen by neuropsychology, please let me know via the neurology secretary copied into the letter and I will refer you back to their service for review.

Kind regards,

Dr Fenech

ST6 Neurology Registrar

Electronically Signed: Dr Fenech, Consultant

cc. GP - sent electronically

Printed on 11/05/2026 08:51 by McLoughlin

Page 1 of 1

Scanned Document
 03-Feb-2017 Ms Jane Lindsay
 Additional: Scanned Document
 SCI Referral Letter :

Filename: 008H6004.html

Extension:.lif

Pages:

Hospital use only	Clinic	Day Date	Time	Hospital No.
-------------------	--------	----------	------	--------------

Date Referral Sent ??2017-02-03

REFERRAL LETTER
MEDICAL IN CONFIDENCE

1010129666801
Unique Care Pathway Number: 1010129666801

0209615214

CHI No:0209615214

REFERRAL TO			
Colorectal CancerC1P LAN WISH Sus Colorectal Cancer	?	Consultant / receiving practitionerand/orspecialty clinic	
Lanarkshire Cancer Referral Centre SCI Virtual location code	?	Hospitaland hospital address	
		Hospital unit no. L002G	
		Email address	
Urgency of referral	Urgent Suspicion of? Cancer??		

PATIENT DETAILS		Patient's address	
Surname	HANEY	9 COMMUNITY PLACE BELLSHILL ML4 2DG	
Forename(s)	JAMES		
Title	-		
Sex	Male	Contact number(s)	
Date of birth	02-Sep-1961	Voice:01698295507	
CHI no.	0209615214		

REFERRING PRACTITIONER DETAILS		Practice address	
Name	Dr S Findlay	2 POLLOCK STREET LANARKSHIRE	
GMC code	4158127	GP code 10677	
Practice name	Medical Centre		
Practice code	62031	Contact number(s)	
		Voice:01698747666	

Additional Administrative Information	
Is the patient physically fit for outpatient bowel preparation:Yes	
SHOULD THE PATIENT BE TREATED WITH MILITARY VETERAN PRIORITY :No	
Is Patient Transport Required:No	
?	

CLINICAL INFORMATION**History of presenting complaint / examination findings / investigation results****Presenting complaint**

Main presenting Complaint: weight loss, altered bowel habit

Reason for Referral: Dear Doctor

I would be grateful if you would review this 55 year old gentleman who has had previous scopes for a similar presentation.

He reports a 3 - 4 month history of altered bowel habit swinging from constipation to occasional loose stools with urgency. He reports occasional tenesmus and also some unintentional weight loss recently with a poor appetite, tiredness all the time and lethargy.

On examination his abdomen was soft and he was tender in the suprapubic region as well as the left renal angle. I have referred him for urgent bloods and would be grateful if you would consider him for scope.

Yours sincerely

Examinations and Investigations

Rectal Bleeding: No -
 Passage of mucus: No -
 Tenesmus: Yes -
 Anal Symptoms: Yes -
 Change in bowel habit greater than 4 weeks: Yes -
 Abdominal mass palpable: No -
 Rectal lesion palpable: No -
 qFIT test given to patient (see Guidelines): No -

Reason for referral

Care type requested: Out Patient
 Expected outcome: Not Specified

Past medical history**High and Medium Priority Pre-existing conditions**

Description	?? Laterality	?? Modifier	?? Extension	?? Date Recorded
[X]Major depression, moderately severe	?? -	??	?? New event	?? -
Basal cell carcinoma	?? -	?? -	?? nose : DATE_RECORDED=29/07/2010	?? -

Current medication (Active Repeat medication issued within the last 12 months)

Drug name	?? BNF code	?? Formulation	?? Dosage	?? Frequency	?? Course started	?? Duration
Omeprazole 20mg gastro-resistant capsules	?? 69782020	?? capsule	?? 1 CAP DAILY	?? -	?? 30-Oct-2013	?? -

Recent medication (Any medication issued within last 90 days not shown above)

No recent medications recorded

Clinical warnings

Lifestyle risks
 Exercise status: Not Known

Smoking status

Number per day
 ??(not known)

Alcohol consumption

Units per day
 ??(not known)

Additional Clinical information

}}>

 Signature of referring doctor (or other professional) Date

Scanned Document

13-Oct-2015 Mrs Allison Mitchell

Additional: Scanned Document

SCI Referral Letter :

Filename: 008H6003.html

Extension:.tif

Pages:

Hospital use only	Clinic	Day Date	Time	Hospital No.
-------------------	--------	----------	------	--------------

Date Referral Sent ??2015-10-13

REFERRAL LETTER
MEDICAL IN CONFIDENCE

101010118330D

Unique Care Pathway Number: 101010118330D

0209615214

CHI No:0209615214

REFERRAL TO	
DermatologyA7 LAN General Referral	? Consultant / receiving practitioner and/or specialty clinic
Wishaw General Hospital 50 Netherton Street Wishaw ML2 0DP	? Hospital and hospital address
	Hospital unit no. L3088
	Email address
Urgency of referral	Routine???

PATIENT DETAILS		Patient's address
Surname	HANEY	9 COMMUNITY PLACE BELLSHILL ML4 2DG
Forename(s)	JAMES	
Title	-	
Sex	Male	
Date of birth	02-Sep-1961	
CHI no.	0209615214	Contact number(s) Voice:01698295507

REFERRING PRACTITIONER DETAILS		Practice address
Name	Dr. Findlay	2 Pollock Street Mossend Bellshill
GMC code	4158127	
GP code	10677	
Practice name	Medical Centre (62031)	
Practice code	62031	Contact number(s) Voice:01698 747666

Additional Administrative Information
SHOULD THE PATIENT BE TREATED WITH MILITARY VETERAN PRIORITY :No
Is Patient Transport Required:No
?

CLINICAL INFORMATION**History of presenting complaint / examination findings / investigation results****Presenting complaint**

Main

presenting lesion on nose

Complaint:

Reason: Dear Doctor

for

Referral: Please can you take time to see James once again who had a basal cell carcinoma removed from the left side of his nose in 2010. Despite my correcting him James still referred to this as a melanoma however I have checked and it was definitely a basal cell carcinoma. Unfortunately just proximal to his scar he has developed a regular, pink, round, firm lesion. It has no suspicious features but James is understandably anxious about it and was keen for referral. I would appreciate if you could have a peek at it.

Yours sincerely

Reason for referral

Care type requested: Out Patient

Expected outcome: Not Specified

Past medical history**High and Medium Priority Pre-existing conditions**

Description	?? Laterality	?? Modifier	?? Extension	?? Date Recorded
[X]Major depression, moderately severe	?? -	??	?? New event	?? 11-Feb-2014
Basal cell carcinoma	?? -	?? -	?? nose : DATE_RECORDED=29/07/2010	?? 18-Jun-2010

Current medication (Active Repeat medication issued within the last 12 months)

No current medications recorded

Recent medication (Any medication issued within last 90 days not shown above)

Drug name	?? BNF code	?? Formulation	?? Dosage	?? Frequency	?? Course started	?? Duration
Ibuprofen 5% gel	?? 77459070	?? gram	?? APPLY THREE TIMES DAILY TO TH[mm]	?? -	?? 07-Oct-2015	?? -
Proctosedyl ointment (Sanofi)	?? 51284020	?? gram	?? APPLY TWICE DAILY	?? -	?? 07-Oct-2015	?? -
Mirtazapine 15mg tablets	?? 88879020	?? tablet	?? 1 TABLET ONCE A DAY AT NIGHT	?? -	?? 03-Sep-2015	?? -

Clinical warnings

Smoking status

Alcohol consumption

Lifestyle risks

Number per day

Units per day

Exercise status: Not Known

??(not known)

??(not known)

Additional Clinical information

}}>

Signature of referring doctor (or other professional) Date

Scanned Document

13-Feb-2014 Mrs Allison Mitchell

Additional: Scanned Document

SCI Referral Letter :

Filename: 008H6002.html

Extension: .tif

Pages:

Hospital use only	Clinic	Day Date	Time	Hospital No.
-------------------	--------	----------	------	--------------

Date Referral Sent ??2014-02-13

REFERRAL LETTER
MEDICAL IN CONFIDENCE

101006724627F

0209615214

Unique Care Pathway Number: 101006724627F

CHI No:0209615214

REFERRAL TO	
General Surgery C1 LAN General Referral	? — Consultant / receiving practitioner and/or specialty clinic
Wishaw General Hospital 50 Netherton Street Wishaw ML2 0DP	? — Hospital and hospital address
	Hospital unit no. L3088
	Email address
Urgency of referral	Routine???

PATIENT DETAILS		Patient's address
Surname	HANEY	9 COMMUNITY PLACE BELLSHILL LANARKSHIRE ML4 2DG
Forename(s)	JAMES	
Title	-	
Sex	Male	
Date of birth	02-Sep-1961	Contact number(s)
CHI no.	0209615214	Voice: 295507

REFERRING PRACTITIONER DETAILS		Practice address
Name	Dr. Sanjeev Dhillon	2 Pollock Street Mossend Bellshill
GMC code	6076851 GP code 14061	
Practice name	Medical Centre (G2031)	
Practice code	62031	Contact number(s)
		Voice: 01698 747666

Additional Administrative Information
SHOULD THE PATIENT BE TREATED WITH MILITARY VETERAN PRIORITY : No
Is Patient Transport Required: No
?

CLINICAL INFORMATION**History of presenting complaint / examination findings / investigation results****Presenting complaint**

Main

presenting colonoscopy

Complaint:

Reason for Dear Doctor

Referral:

This patient presents with a one year history of persistent peri-anal irritation and itch. This has failed to settle with courses of suppositories and topical haemorrhoid treatments. He also has frequency of stool and lower abdominal colic. This has failed to settle with a trial of anti-spasmodic's and I would be grateful if he could be seen for colonoscopy to further investigate his symptoms.

Yours sincerely

Reason for referral

Care type requested: Out Patient

Expected outcome: Not Specified

Past medical history**High and Medium Priority Pre-existing conditions**

Description	?? Laterality	?? Modifier	?? Extension	?? Date Recorded
Basal cell carcinoma	?? -	?? -	?? nose	DATE_RECORDED=29/07/2010 ?? 18-Jun-2010

Current medication (Active Repeat medication issued within the last 12 months)

Drug name	?? BNF code	?? Formulation	?? Dosage	?? Frequency	?? Course started	?? Duration
Fybogel Mebeverine effervescent granules sachets orange (...)	?? 52040020	?? sachet	?? 52040020Fybogel Mebeverine effervescent granules sachets orange (...sachet1 SACHET TWICE DAILY2013-10-30	?? -	?? Oct-2013	?? -
Omeprazole 20mg gastro-resistant capsules	?? 69782020	?? capsule	?? 69782020Omeprazole 20mg gastro-resistant capsulescapsule1 CAP DAILY2013-10-30	?? -	?? Oct-2013	?? -

Recent medication (Any medication issued within last 90 days not shown above)

Drug name	?? BNF code	?? Formulation	?? Dosage	?? Frequency	?? Course started	?? Duration
Lotriderm cream (Teva UK Ltd)	?? 58910020	?? gram	?? 58910020Lotriderm cream (Teva UK Ltd)gramTWICE A DAY2014-02-11	?? -	?? Feb-2014	?? -
Citalopram 20mg tablets	?? 79462020	?? tablet	?? 79462020Citalopram 20mg tablettablet1 TABLET DAILY2014-02-11	?? -	?? Feb-2014	?? -
Laxido Orange oral powder sachets sugar free (Galen Ltd)	?? 98714020	?? sachet	?? 98714020Laxido Orange oral powder sachets sugar free (Galen Ltd)sachet1 SACHET AS DIRECTED2013-12-31	?? -	?? Dec-2013	?? -
Proctosedyl ointment (Sanofi)	?? 51284020	?? gram	?? 51284020Proctosedyl ointment (Sanofi)gramAPPLY TWICE DAILY2013-12-31	?? -	?? Dec-2013	?? -

Clinical warnings**Lifestyle risks**

Exercise status: Not Known

Smoking status

Alcohol consumption

Number per day
??(not known)Units per day
??(not known)**Additional Clinical information**

}}>

Signature of referring doctor (or other professional)	Date
---	------

Scanned Document

30-July-2012 Mrs Patricia Mcquade

Additional:Scanned Document

SCI Referral Letter :

Filename: 008H6001.html

Extension:.tif

Pages:

Hospital use only	Clinic	Day Date	Time	Hospital No.
-------------------	--------	----------	------	--------------

Date Referral Sent ??2012-07-30

REFERRAL LETTER
MEDICAL IN CONFIDENCE

1010039658292

Unique Care Pathway Number: 1010039658292

0209615214

CHI No:0209615214

REFERRAL TO	
General Surgery C1 LAN General Referral	? — Consultant / receiving practitioner and/or specialty clinic
Wishaw General Hospital 50 Netherton Street Wishaw ML2 0DP	? — Hospital and hospital address Hospital unit no. [L308H] Email address
Urgency of referral Routine??	

PATIENT DETAILS		Patient's address
Surname	HANEY	9 COMMUNITY PLACE BELLSHILL LANARKSHIRE ML4 2DG
Forename(s)	JAMES	
Title	-	
Sex	Male	
Date of birth	02-Sep-1961	Contact number(s)
CHI no.	0209615214	Voice: 295507

REFERRING PRACTITIONER DETAILS		Practice address	
Name	Dr D J Park	2 POLLOCK STREET BELLSHILL LANARKSHIRE	
GMC code	1347964	GP code	13366
Practice name	Medical Centre	Contact number(s)	
Practice code	62031	Voice: 01696747666	

Additional Administrative Information
Name of person making referral :Dr S Dillon
SHOULD THE PATIENT BE TREATED WITH MILITARY VETERAN PRIORITY :No
Is Patient Transport Required:No
?

?

CLINICAL INFORMATION**History of presenting complaint / examination findings / investigation results****Presenting complaint**

Main presenting colonoscopy

Complaint:

Reason for: Dear Doctor

Referral:

I would be grateful if you could see this gentleman who presents with a mucus type discharge with associated soft loose stool for the past 6 weeks. There is no pr bleeding or abdominal pain. On examination there is nothing to find per rectum. Given the duration of his symptoms I would be grateful if you could organise a colonoscopy. I have also checked his routine bloods.

Yours sincerely

Dr S Dhillon

Reason for referral

Care type requested: Out Patient

Expected outcome: Not Specified

Past medical history**High and Medium Priority Pre-existing conditions**

Description	?? Laterality	?? Modifier	?? Extension	?? Date Recorded
Basal cell carcinoma	?? -	?? -	?? nose	DATE_RECORDED=29/07/2010 ?? 18-Jun-2010

Current medication (Active Repeat medication issued within the last 12 months)

Drug name	?? BNF code	?? Formulation	?? Dosage	?? Frequency	?? Course started	?? Duration
Venlafaxine 150mg modified-release capsules	?? 11223002	?? capsule	?? 1 Cap	In the morning	?? -	?? 12-Jan-2011 ?? -
Propranolol 80mg modified-release capsules	?? 04621001	?? capsule	?? 1 Cap	Daily	?? -	?? 20-Mar-2008 ?? -

Recent medication (Any medication issued within last 90 days not shown above)

Drug name	?? BNF code	?? Formulation	?? Dosage	?? Frequency	?? Course started	?? Duration
LANSOPRAZOLE caps(ec)	30mg	?? 07262001	?? capsule	?? TAKE ONE ONCE DAILY	?? -	?? 03-Jul-2012 ?? -
PROCTOSEDYL supp	?? 00790002	?? suppository	?? TWICE A DAY	?? -	?? 03-Jul-2012	?? -

Clinical warnings**Lifestyle risks**

Exercise status: Not Known

Smoking status

Alcohol consumption

Number per day
?(not known)Units per day
?(not known)**Additional Clinical information**

}}>

Signature of referring doctor (or other professional)	Date
---	------

Scanned Document

29-July-2011 Mrs Patricia Mcquade

Additional: Scanned Document

SCI Referral Letter :

Filename: 008H6000.html

Extension: .tif

Pages:

Hospital use only	Clinic	Day Date	Time	Hospital No.
-------------------	--------	----------	------	--------------

Date Referral Sent ??2011-07-29

REFERRAL LETTER
MEDICAL IN CONFIDENCE

101002307883Q

0209615214

Unique Care Pathway Number: 101002307883Q

CHI No:0209615214

REFERRAL TO	
GastroenterologyA9 LAN General Referral	? — Consultant / receiving practitioner and/or specialty clinic
Monklands District General Hospital Monkscourt Avenue Airdrie ML6 0JS	? — Hospital and hospital address Hospital unit no. [106H] Email address
Urgency of referral Routine??	

PATIENT DETAILS		Patient's address
Surname HANEY	Forename(s) JAMES	9 COMMUNITY PLACE BELLSHILL LANARKSHIRE ML4 2DG
Title -	Sex Male	Contact number(s)
Date of birth 02-Sep-1961	CHI no. 0209615214	Voice: 295507

REFERRING PRACTITIONER DETAILS		Practice address
Name Dr. [REDACTED]	GMC code 6026515 GP code 12629	2 Pollock Street Mossend Bellshill
Practice name [REDACTED] Medical Centre (62031)	Practice code 62031	Contact number(s)
		Voice: 01898 747666

Additional Administrative Information
SHOULD THE PATIENT BE TREATED WITH MILITARY VETERAN PRIORITY :No
Is Patient Transport Required:No
?

THIRD PARTY COPY

CLINICAL INFORMATION**History of presenting complaint / examination findings / investigation results****Presenting complaint**

Main
presenting ongoing rectal bleeding for over two years now.
Complaint:

Reason Dear Doctor
for

Referral: I would be very grateful if you would consider seeing this gentleman who has had ongoing rectal bleeding for over two years now. He was previously seen in 2009 and had an endoscopy which showed mild patchy atrophy within the descending colon but he was never followed-up unfortunately. He hasn't reported any weight loss or red flag symptoms however I would be extremely grateful if you would consider assessing this gentleman again.

Yours sincerely

Reason for referral

Care type requested: Out Patient
Expected outcome: Investigate

Past medical history**High and Medium Priority Pre-existing conditions**

Description	?? Laterality	?? Modifier	?? Extension	?? Date Recorded
Basal cell carcinoma	?? -	?? -	?? nose	DATE_RECORDED=29/07/2010 ?? 18-Jun-2010

Current medication (Active Repeat medication issued within the last 12 months)

Drug name	?? BNF code	?? Formulation	?? Dosage	?? Frequency	?? Course started	?? Duration
VENLAFAXINE nr cap 75mg	?? 11223001	?? capsule(s)	?? 1 Cap Daily	?? -	?? 12-Jan-2011	?? -
VENLAFAXINE nr cap 150mg	?? 11223002	?? capsule(s)	?? 1 Cap In the morning	?? -	?? 12-Jan-2011	?? -
PROPRANOLOL nr cap 80mg	?? 04621001	?? capsule(s)	?? 1 Cap Daily	?? -	?? 20-Mar-2008	?? -

Recent medication (Any medication issued within last 90 days not shown above)

Drug name	?? BNF code	?? Formulation	?? Dosage	?? Frequency	?? Course started	?? Duration
CETIRIZINE tabs 10mg	?? 05918001	?? tablet	?? TAKE ONE DAILY	?? -	?? 21-Jul-2011	?? -

Clinical warnings

Lifestyle risks
Exercise status: Not Known

Smoking status

Alcohol consumption

Number per day ??(not known)

Units per day ??(not known)

Additional Clinical information

}}>

_____ Signature of referring doctor (or other professional)	_____ Date
--	---------------